

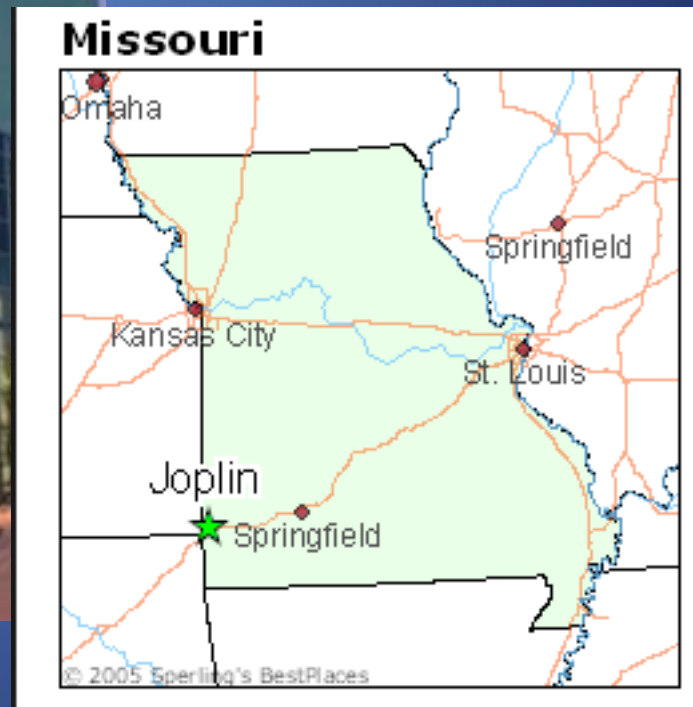ENT Update in Primary Care

Scott McClintick, DO

Freeman Ear, Nose and Throat

Freeman Health Systems - Joplin, MO

- No disclosures



Joplin, Missouri

- Tornado on May 22, 2011
- Opening of KCU-Joplin 2017















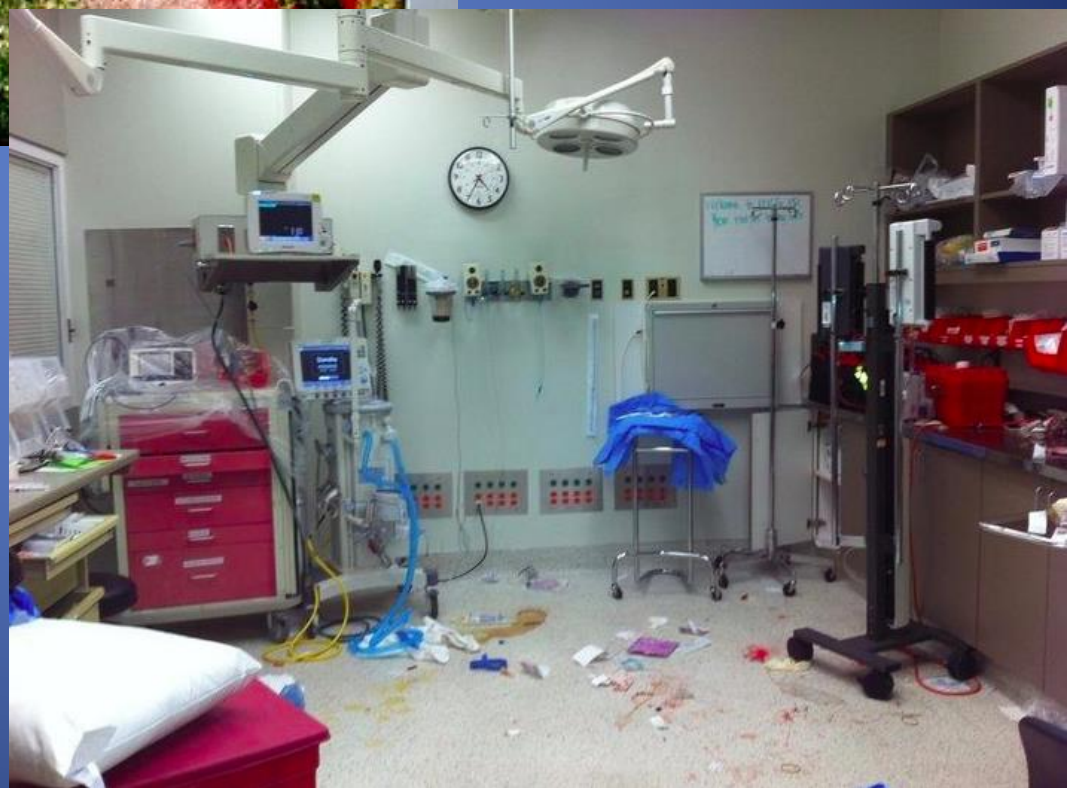



Mercy Hospital







Mercy's Temporary Hospital



KCU-Joplin Construction





ENT disorders are very common in primary care, comprising 20-50% of presenting complaints to a primary care provider

A need for otolaryngology education among primary care providers

Amanda Hu*, Maya G. Sardesai and Tanya K. Meyer

Department of Otolaryngology – Head & Neck Surgery, University of Washington, Seattle, WA, USA

37 PCPs completed a 12-question test on Otolaryngology:

- family medicine: 4.6
- pediatric medicine: 4.2
- adult medicine: 3.9

Primary care perceptions of otolaryngology.

Domanski MC¹, Ashktorab S, Bielasowicz SA.

- Surveyed 1,060 primary care residents
- Found that they are not aware of the scope of practice of otolaryngology:
 - Only 47.2% of primary care residents chose otolaryngologists as experts for thyroid surgery
 - Only 32.4% for sleep apnea

In fact, only 43% of patients are even aware that an otolaryngologist is a physician !

ENT in Primary Care

Otitis Media

Nasal Congestion

Tonsil and Adenoid Disease

Salivary Gland Disorders

Adult Neck Mass

Oropharyngeal Cancer

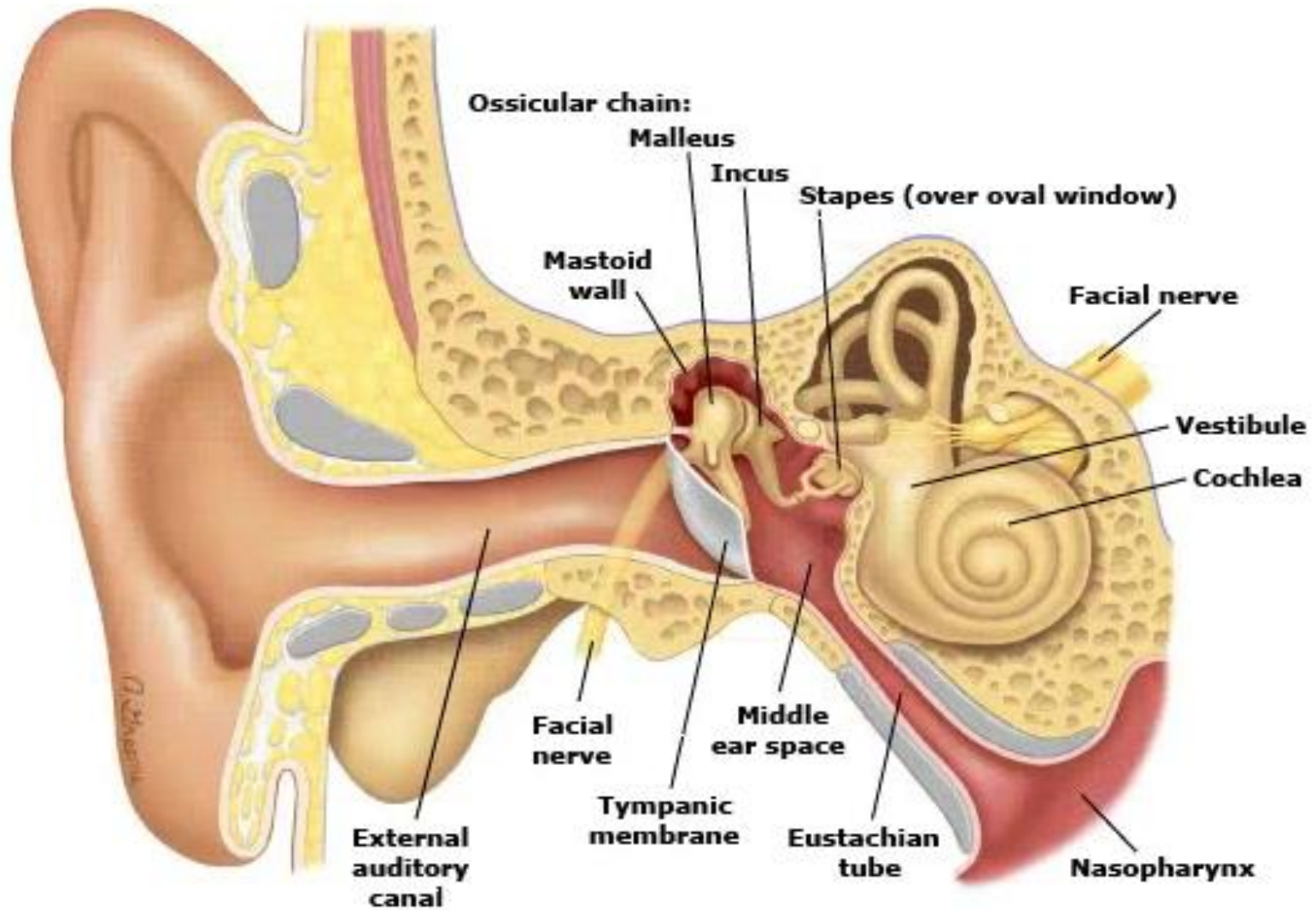
Acute Otitis Media

- **AOM:** most frequent reason for sick child visit
- Most common: 6-24 months of age
- Early onset is best predictor of recurrence
- Risk Factors:
 - Age – AOM peaks at age 6-18 months
 - Lack of breastfeeding
 - Smoke exposure
 - Daycare
 - Other: Down syndrome, cleft palate

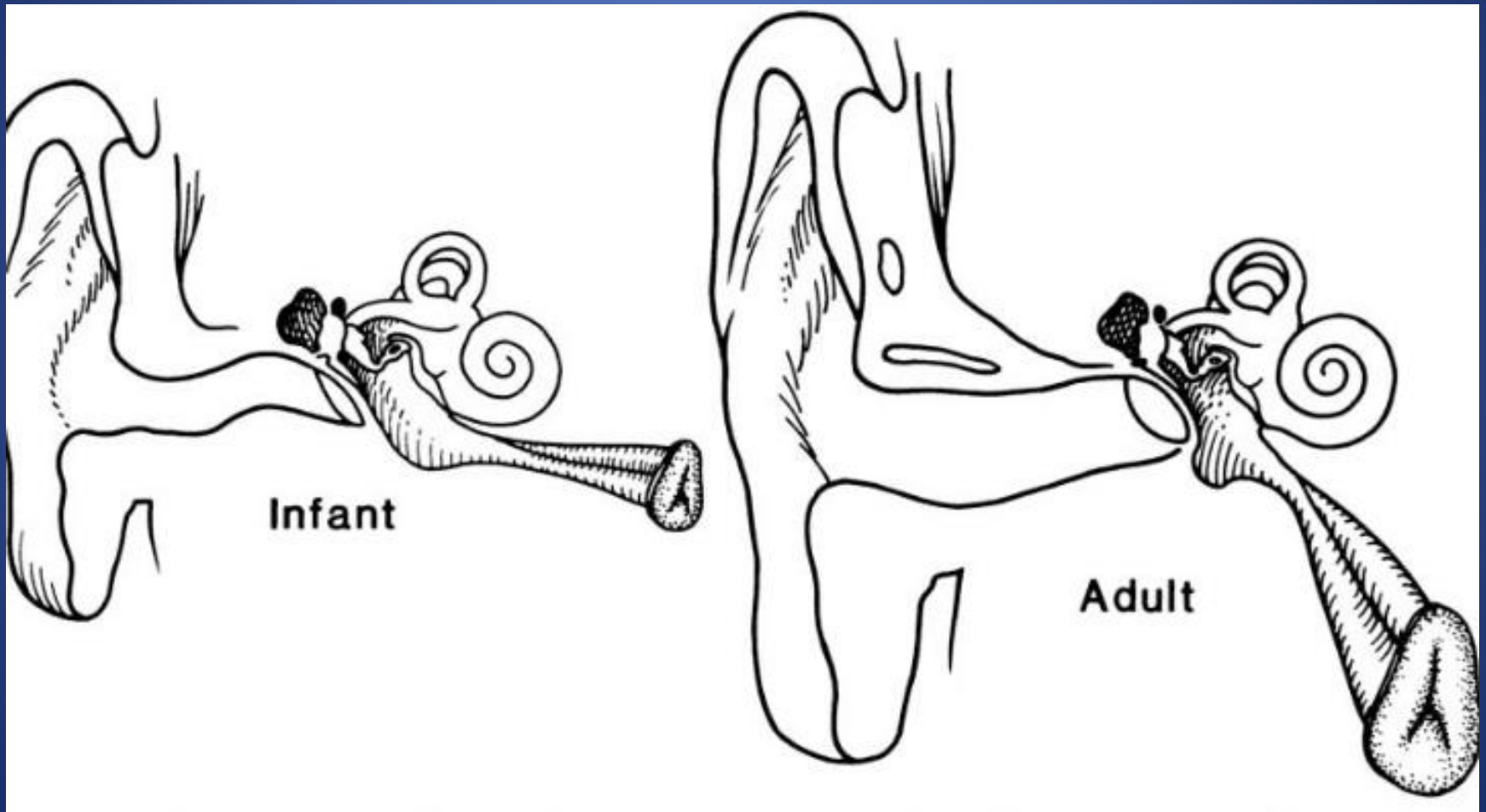
AOM: Diagnosis

- AOM Diagnosis Requires:
 - Signs/Symptoms of middle ear inflammation
 - Erythema of TM, Bulging of TM
 - Middle Ear effusion (air fluid level, decreased mobility)
- Complications/Associated Conditions:
 - Hearing loss
 - Balance problems
 - TM perforation
 - Cholesteatoma
 - Mastoiditis, Meningitis

Middle ear anatomy



Eustachian tube angle



Pathogenesis

URI



Edema of Eustachian tube



Negative pressure in middle ear space



Accumulation of secretions (effusion)



Viral or bacterial contamination



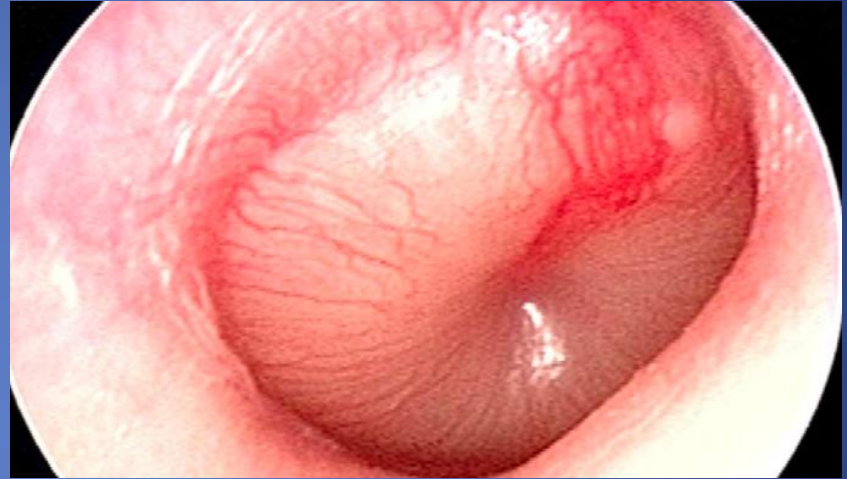Acute Otitis Media

Otitis Media with Effusion

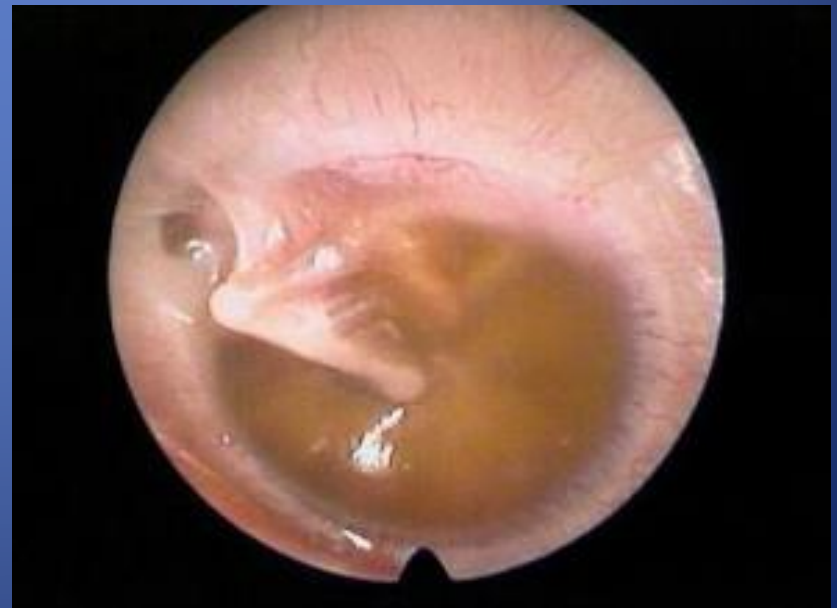- Middle ear fluid WITHOUT acute signs of infection
- Often occurs after AOM
- Usually resolves and observation preferred
 - Except: Hearing loss, speech delay, cleft palate
- **Chronic Otitis Media (with effusion)**
 - OME that persists >3 months
 - Glue ear: effusion becomes thick and “glue-like”

Physical Exam Findings

- Acute Otitis Media



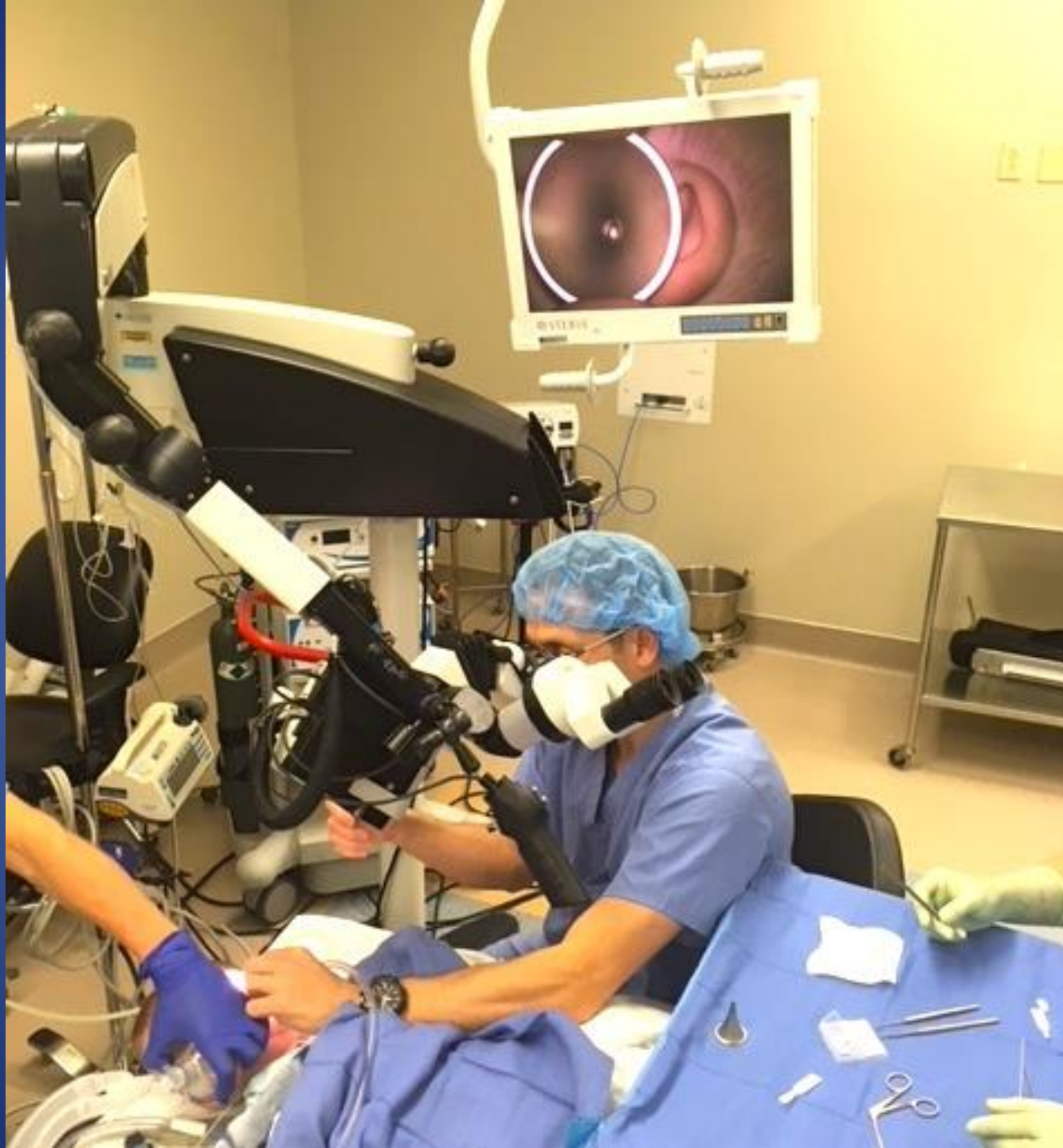
- Chronic Otitis Media

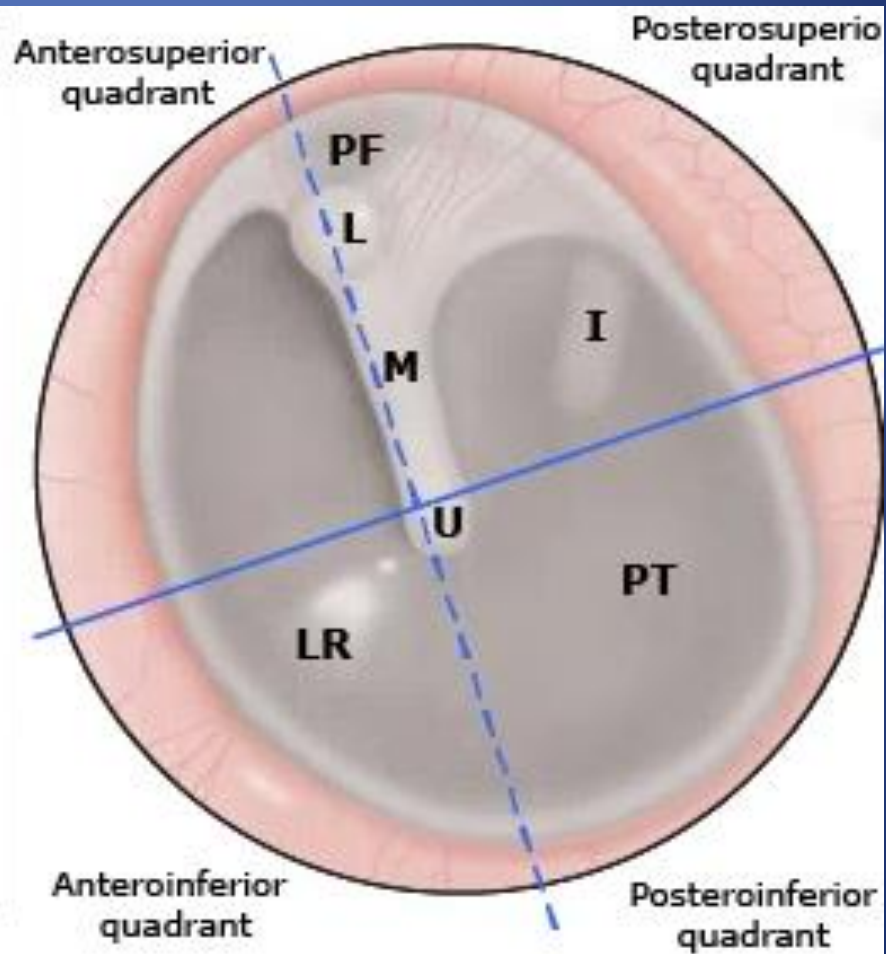
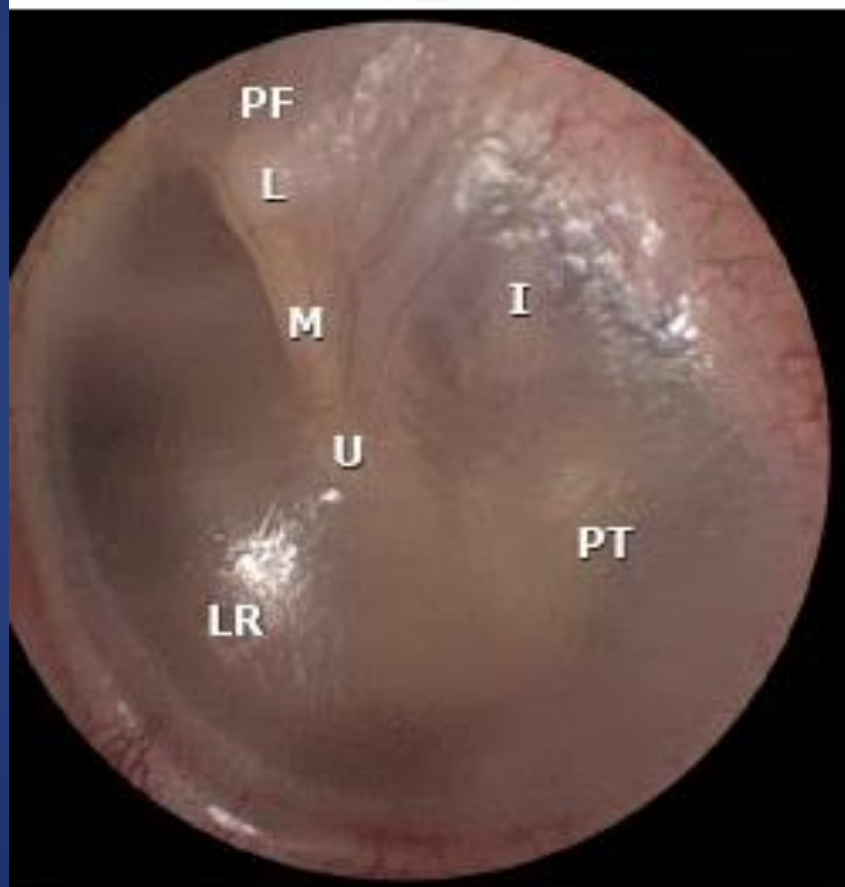


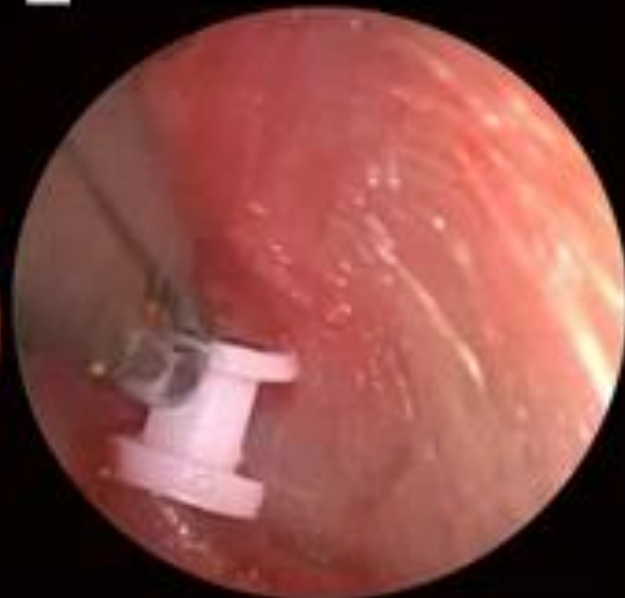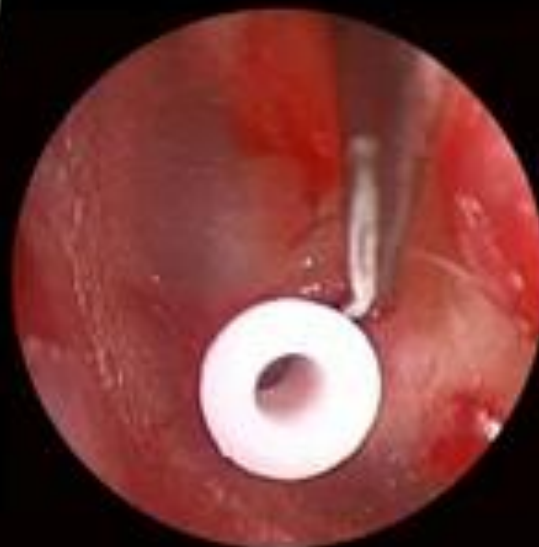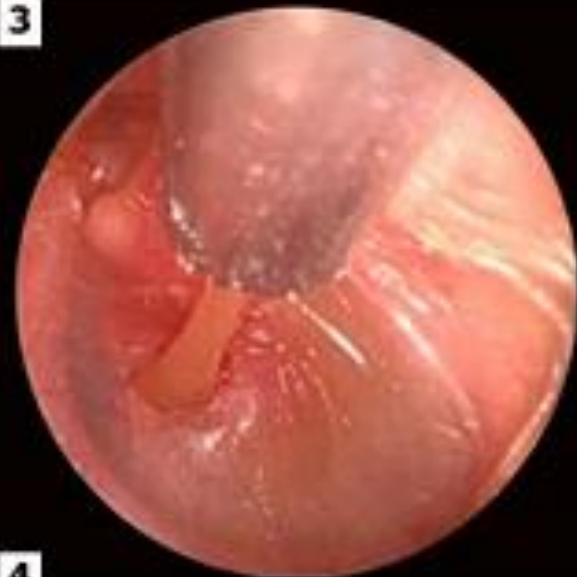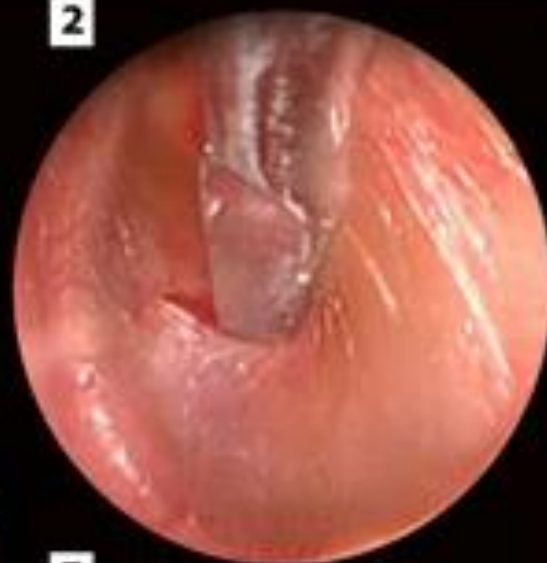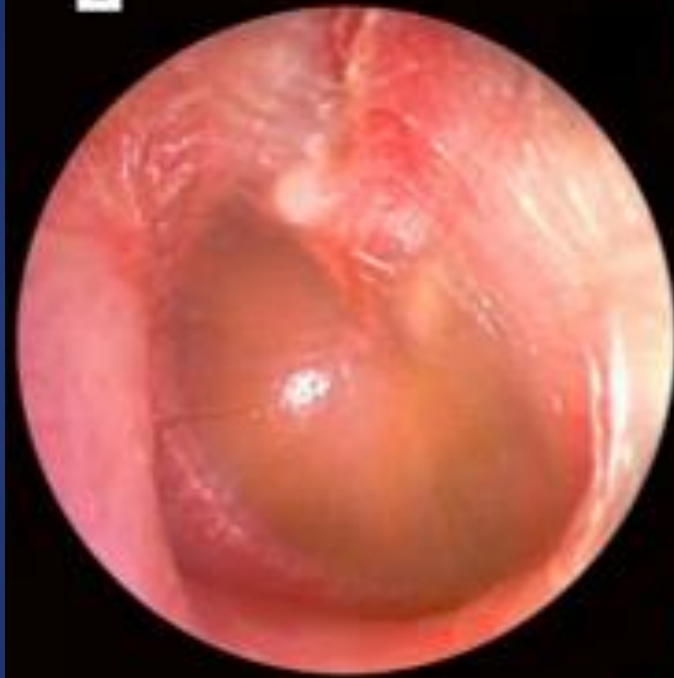Tympanostomy Tubes

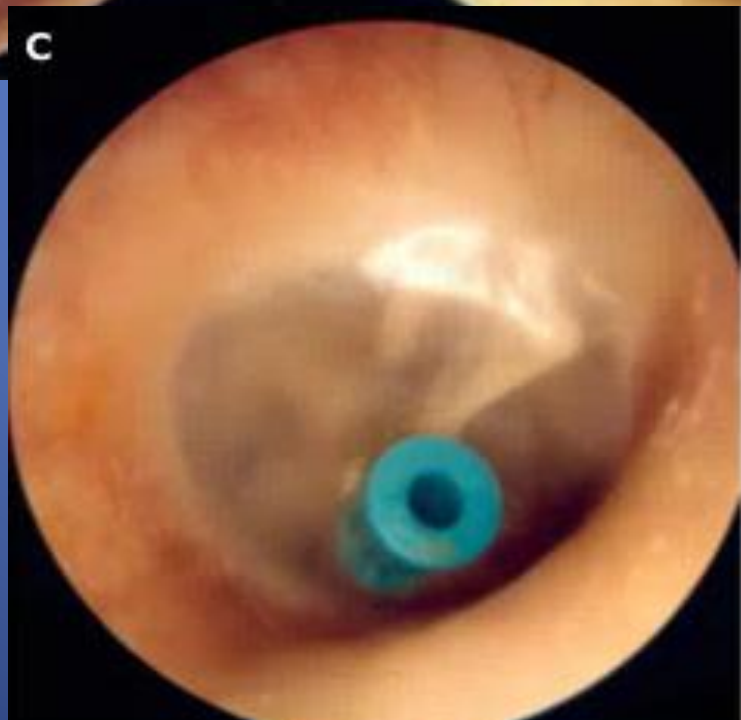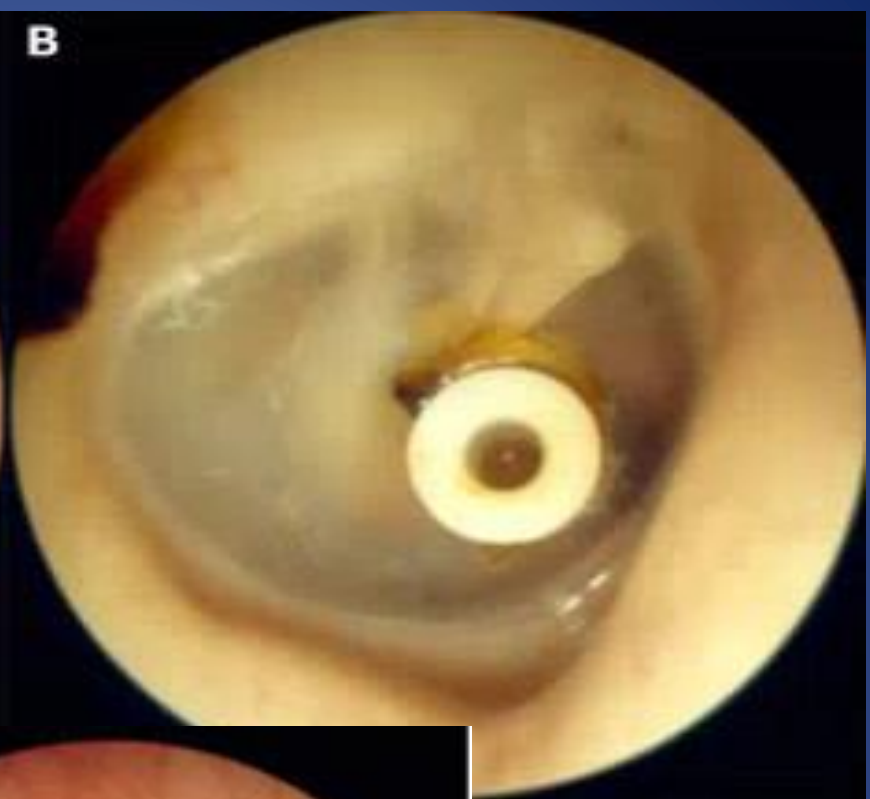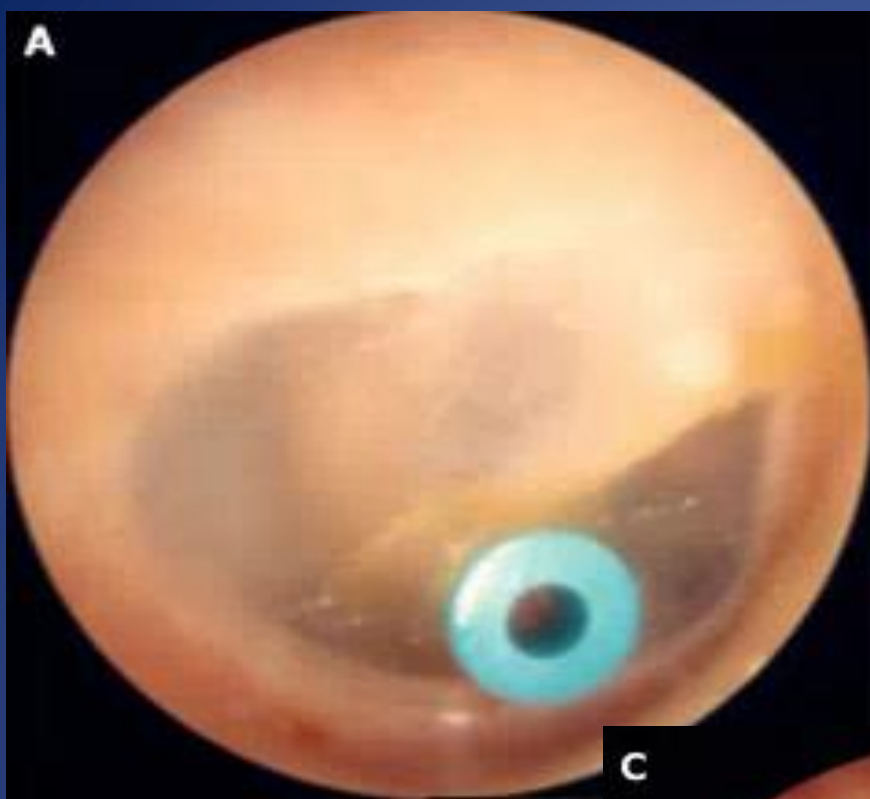
- >675,000 performed annually
- Pressure Equalization tubes, Ventilation tubes
- Under-ventilation of middle ear space is cause of otitis media
- Myringotomy: surgical perforation
- *1900's*: fish bones, lead wire, gold rings were used











AOM/COM: When to Refer

- **Recurrent AOM:**
 - 3 or more episodes in past 6 months
 - 4 or more episodes in the past 12 months
- **Chronic OM:**
 - OME persisting for > 3 months
 - Hearing loss, balance issues, poor school perform.
- **Chronic draining ear/TM perforation**

Nasal Congestion

- Among most common reasons for primary care visits
- Defined: sensation of insufficient nasal airflow
- Generally divided into mucosal and structural causes

Nasal Congestion

- **Inflammatory**

- Rhinosinusitis
- Allergic Rhinitis
- Nasal Polyps
- Wegner's, Sarcoid

- **Infectious**

- HIV
- Syphilis
- TB
- Nasal Vestibulitis

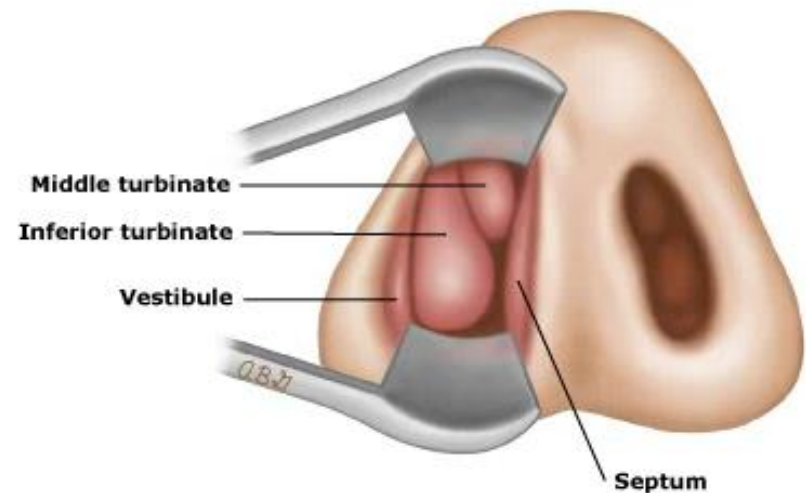
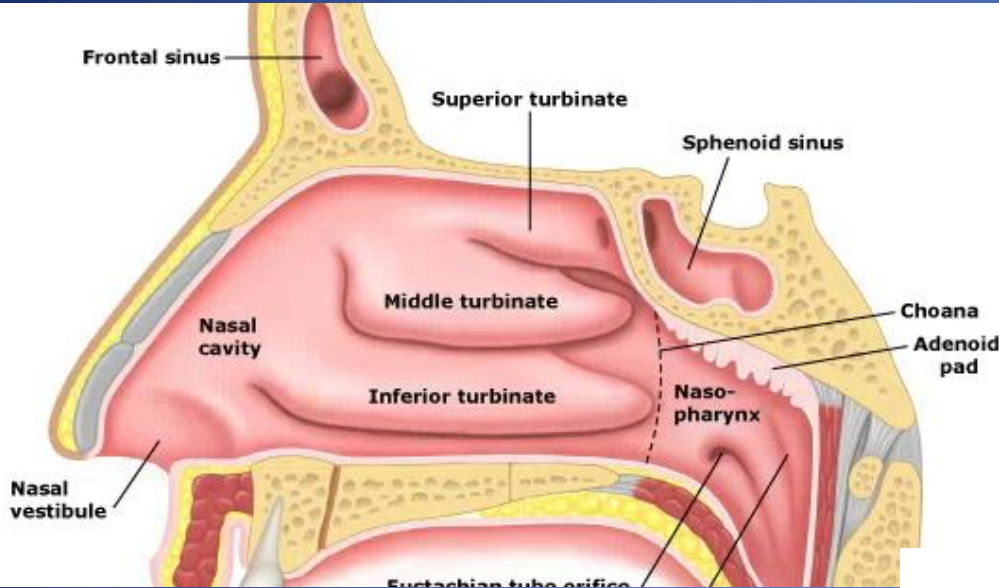
- **Medication**

- Antithyroid meds
- Antihypertensive meds
- Antidepressants/Benzos
- NSAIDS
- Oxymetazoline/Neosynepherine

- **Structural**

- Adenoid hypertrophy
- Turbinate hypertrophy
- Foreign body
- Septal deviation, perforation
- Nasal valve abnormalities

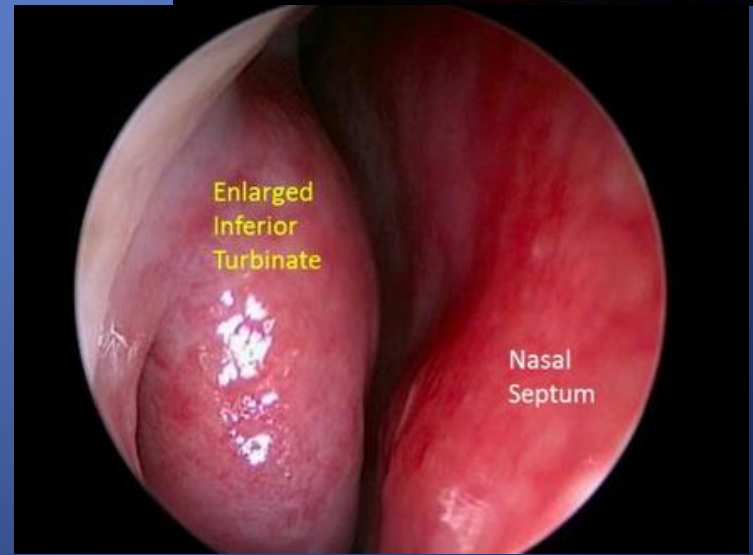
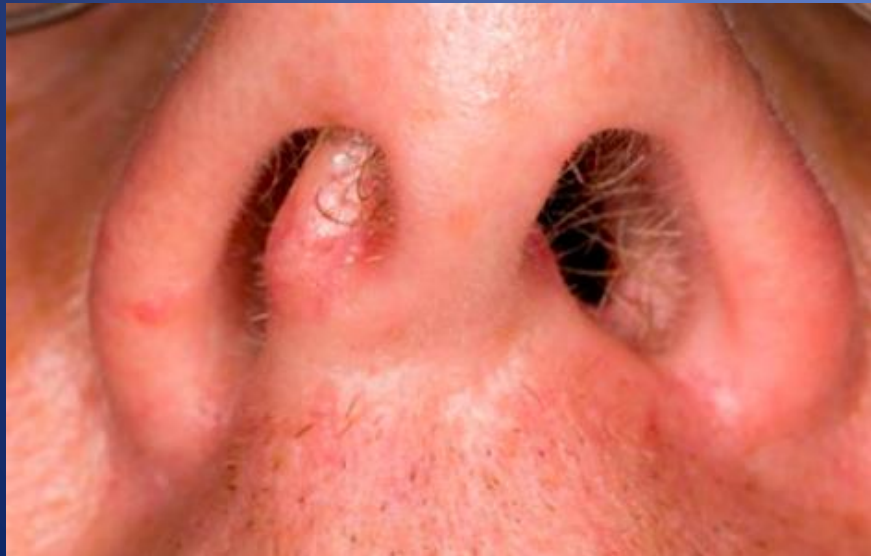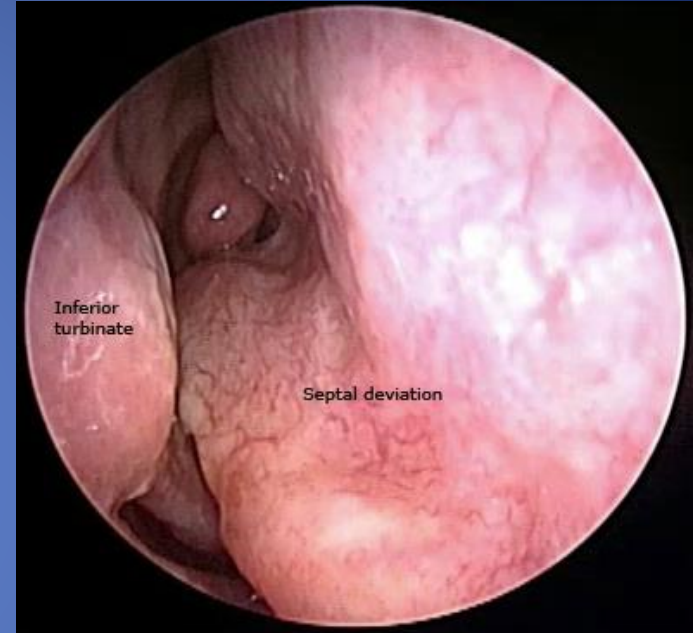
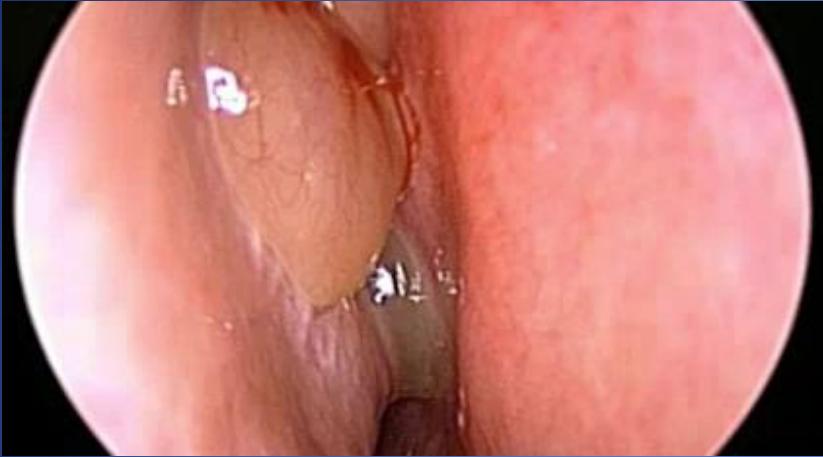
Nasal Congestion: Anatomy



Nasal Congestion: **Diagnosis**

- History:
 - **Location:** Unilateral vs Bilateral
 - **Time course:** seasonal
 - **Triggers:** Allergic stimuli, work environment
 - **Symptoms of sinusitis:** facial pressure, purulence
 - **Symptoms of malignancy:** facial deformity, CN dysfunction, unexplained epistaxis
 - **Intranasal drug use:** cocaine, topical decongestants
 - **Oral Meds**
 - **Trauma:** History of nasal trauma (septal hematoma)

Nasal Congestion: Physical Exam



Nasal Congestion: Treatment

- Target underlying etiology
- Intranasal steroids are first-line therapy for most conditions
- Review medication list and discontinue if possible

Nasal Congestion: Treatment

- **Nasal Vestibulitis**
 - Warm compresses and mupirocin ointment BID x 5 days
 - Consider oral abx if severe
- **Rhinitis/Turbinate hypertrophy**
 - Allergen avoidance, oral antihistamines and intranasal steroids
 - Saline irrigations !!!
 - Inferior turbinate reduction is effective
- **Medication induced: Rhinitis Medicamentosa**
 - Discontinue nasal decongestants (one side at a time)
 - Start nasal steroids (consider oral steroids short term)
 - Prevention is key
- **Deviated nasal septum**
 - Septoplasty is definitive treatment (90+ % effective)
 - Septal button for perforations
- **Nasal valve collapse**
 - Surgery is sometimes required
 - Nasal strips at night are effective

Nasal Congestion: **When to Refer**

- **Patients with potentially serious nasal or sinus complaints**
 - Facial deformity, CN dysfunction, unexplained epistaxis
- **Patients with structural etiology for congestion**
 - Septal deviation, turbinate hypertrophy, valve collapse
- **Patients with mucosal etiology for congestion**
 - Initiation of nasal steroids is appropriate

Tonsil and Adenoid Disease

- Recurrent and chronic adenotonsillitis is common complaint in primary care setting
- Perhaps less recognized is Adenotonsillar Hypertrophy with associated Sleep Disordered Breathing
- Tonsils/Adenoids:
 - Lymphoepithelial organs, initiating immune response against inspired antigens
 - Greatest immunological activity b/w age 3-10
 - Demonstrate age-dependent involution

Tonsillectomy and Adenoidectomy

- >500,000 performed annually
- Safe procedure
- One of the most common ambulatory surgeries
- Risks:
 - Dehydration
 - VPI
 - Post-op bleeding (5%) up to 2 weeks

Tonsillectomy & Adenoidectomy: Indications

- Infections
 - 7 infections in 1 year
 - 5 infections per year x 2 years
 - 3 infections per year x 3 years
 - Chronic tonsillitis, tonsilloliths, halitosis
- Obstructive sleep apnea / Sleep disordered breathing
 - secondary to Adenotonsillar hypertrophy
- Recurrent peritonsillar abscess
- Tonsillar asymmetry

Pediatric OSA / Sleep Disordered Breathing

- Most common indication for T&A
- OSA occurs in up to 5% of children
- Most commonly 2-6 years of age
- Adenotonsillar hypertrophy is most common cause
- Obesity is also risk factor

Sleep Disordered Breathing

Represents a Spectrum of disorders

Primary Snoring-----Obstructive Sleep Apnea

Sleep Disordered Breathing

- **Children with SDB:**
 - Higher rate of abx usage
 - 40% more hospital visits
 - Lower QoL scores
 - Physical functioning, behavior, caregiver impact
- **Hyperactivity, Anxiety, Aggression, Enuresis**
 - QoL of children with OSA is similar to chronic conditions such as Asthma and Juvenile RA

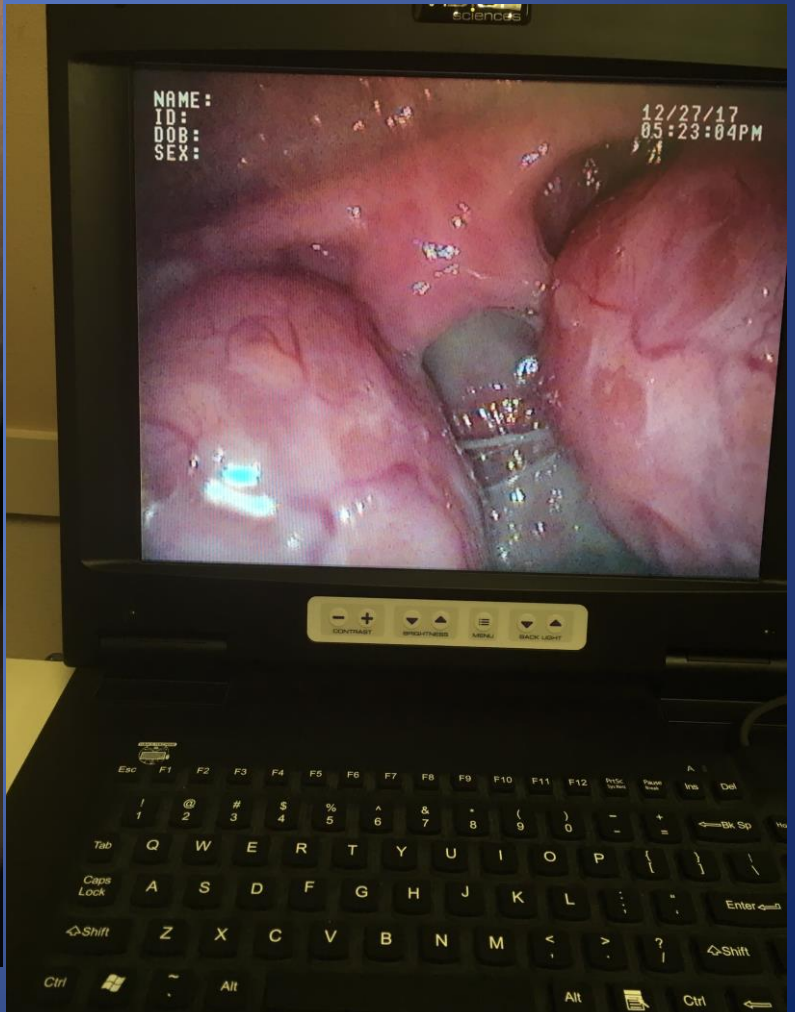
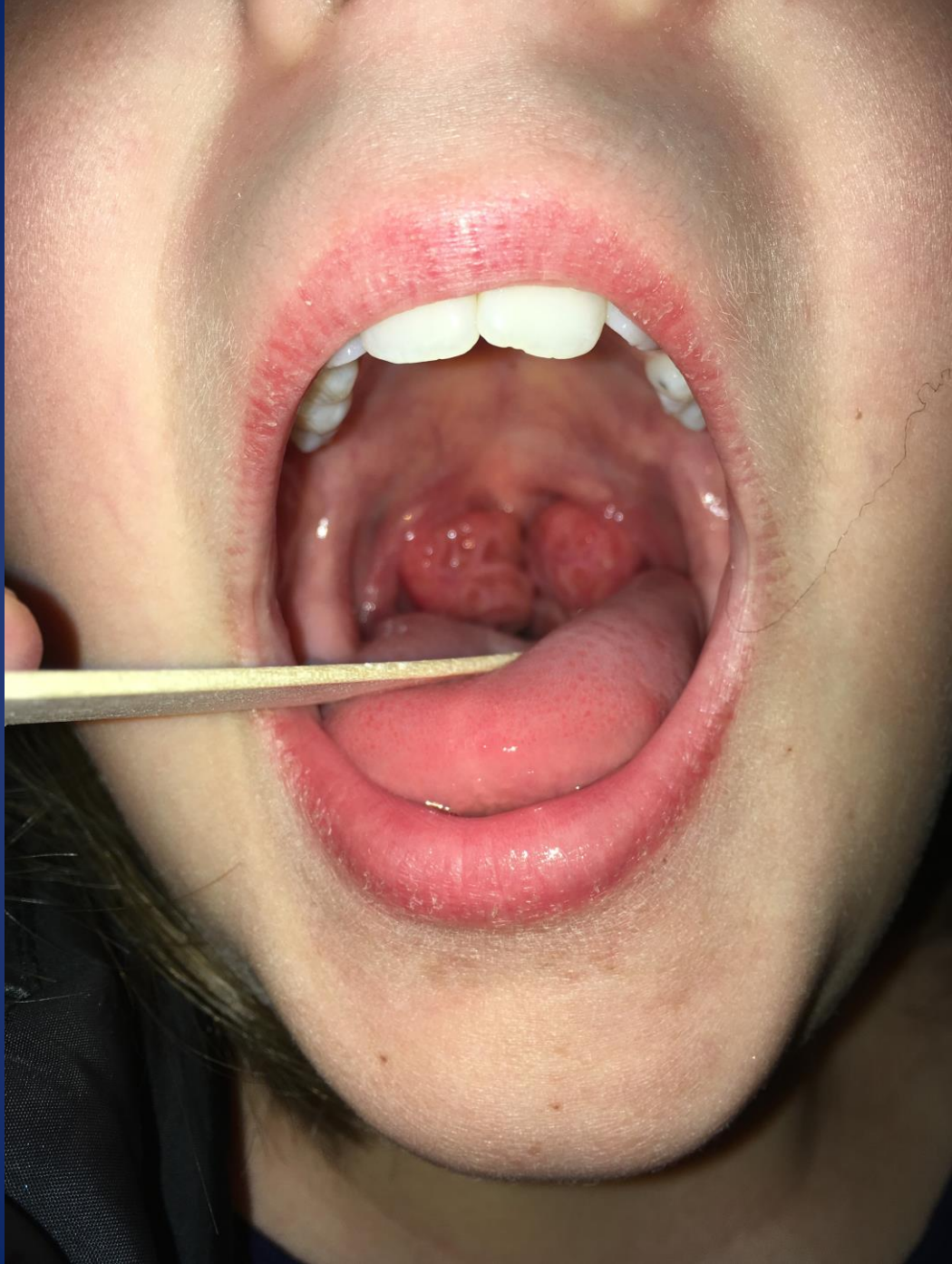Sleep Disordered Breathing: Symptoms

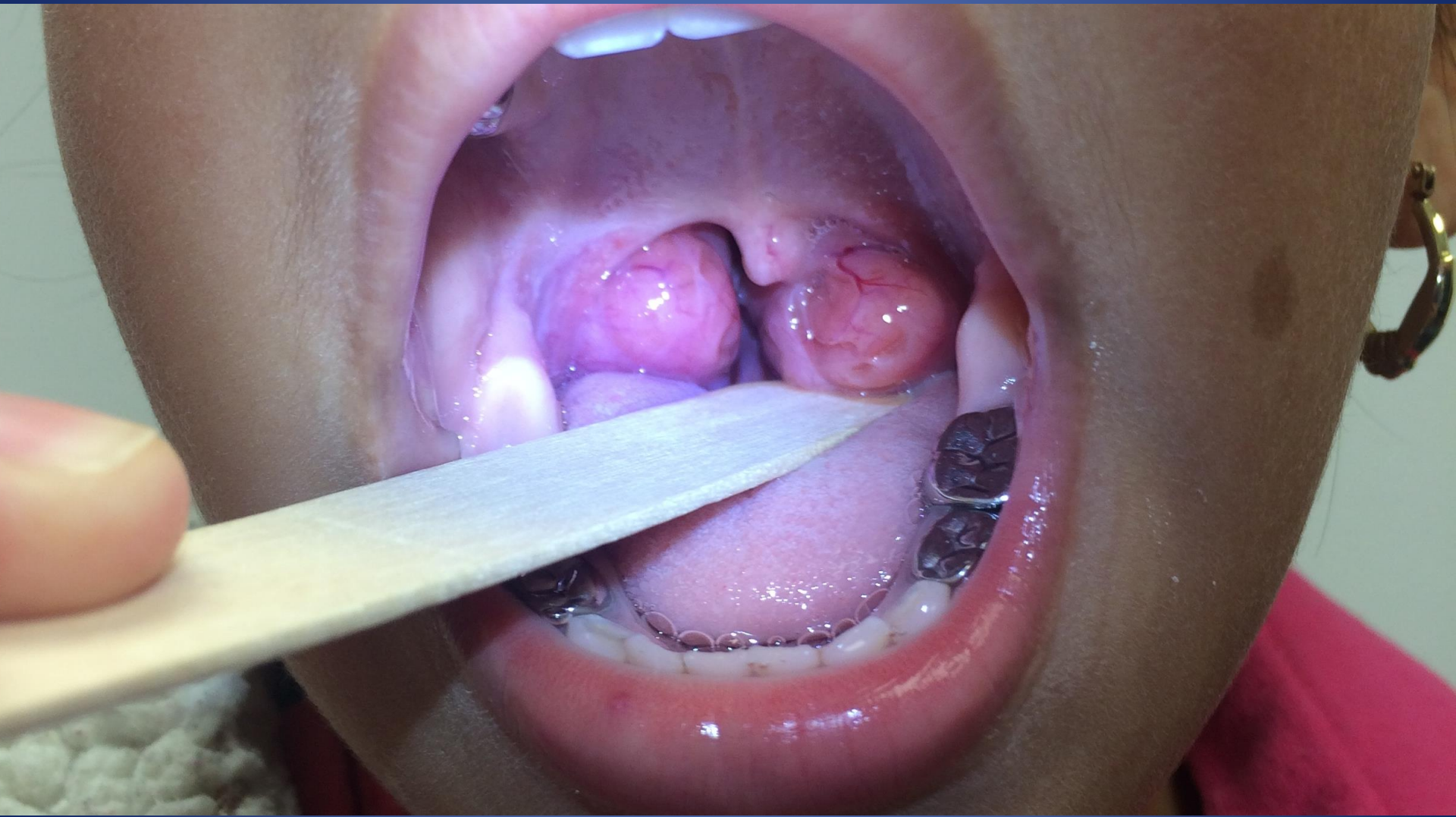- Snoring (“snores like grandpa”)
- Mouth breathing or noisy breathing
- Pauses in breathing (Apnea)
- RESTLESS SLEEPING (Toss turn, Flip flop)
- Nocturnal enuresis !
- Sleepwalking/Night terrors
- Daytime sleepiness
- Learning and behavioral problems (mistaken for ADHD) !

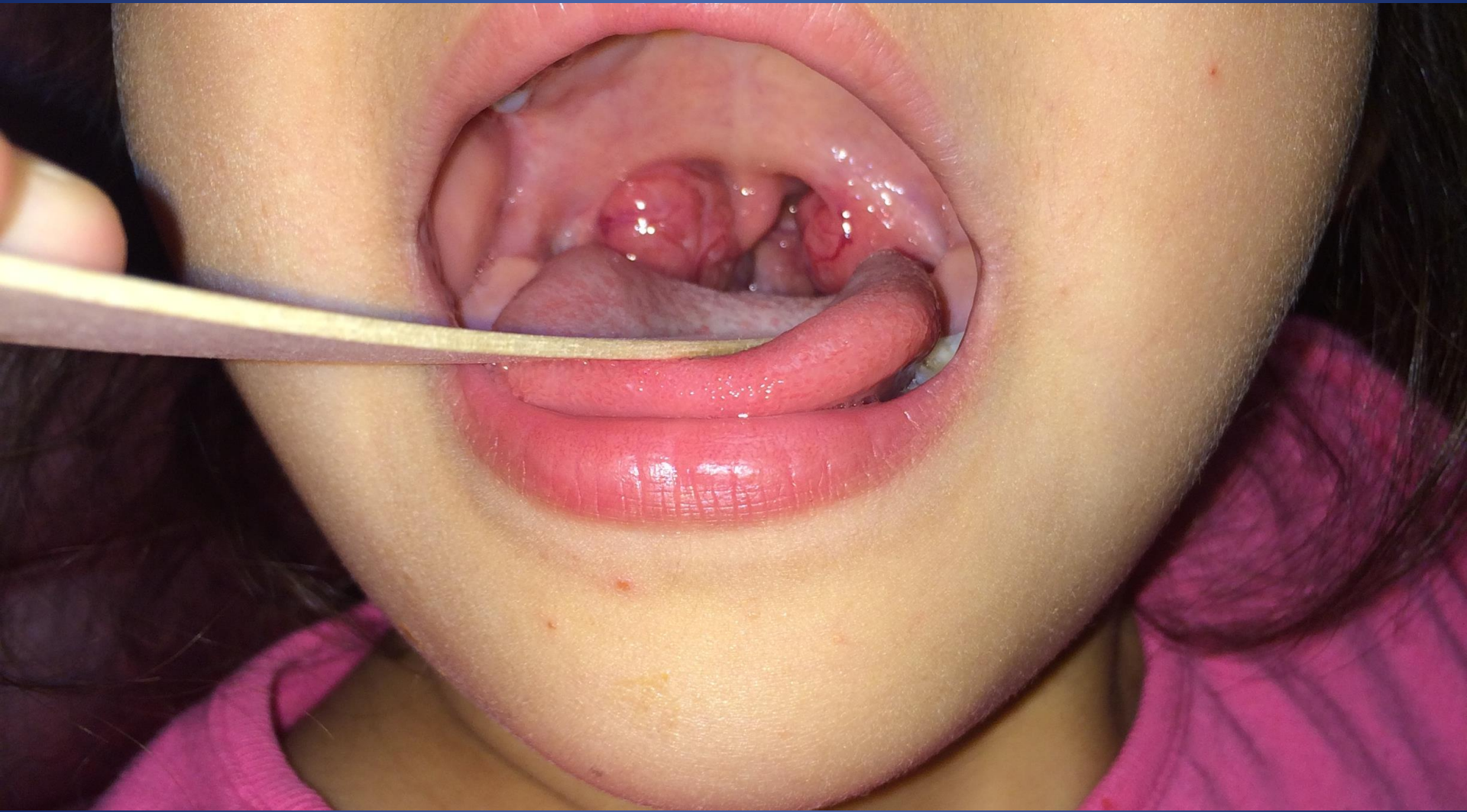

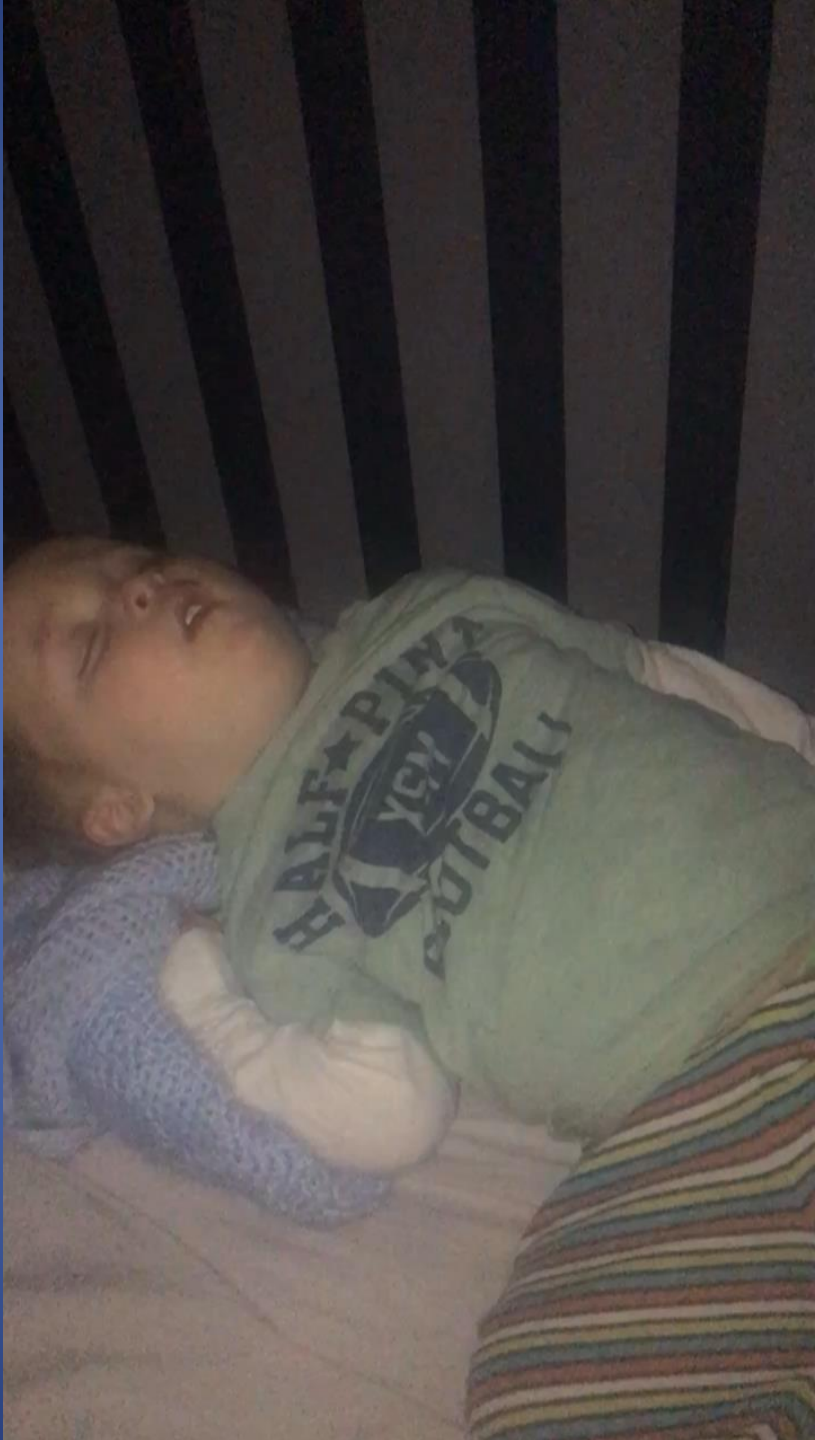Peds OSA: **Diagnosis**

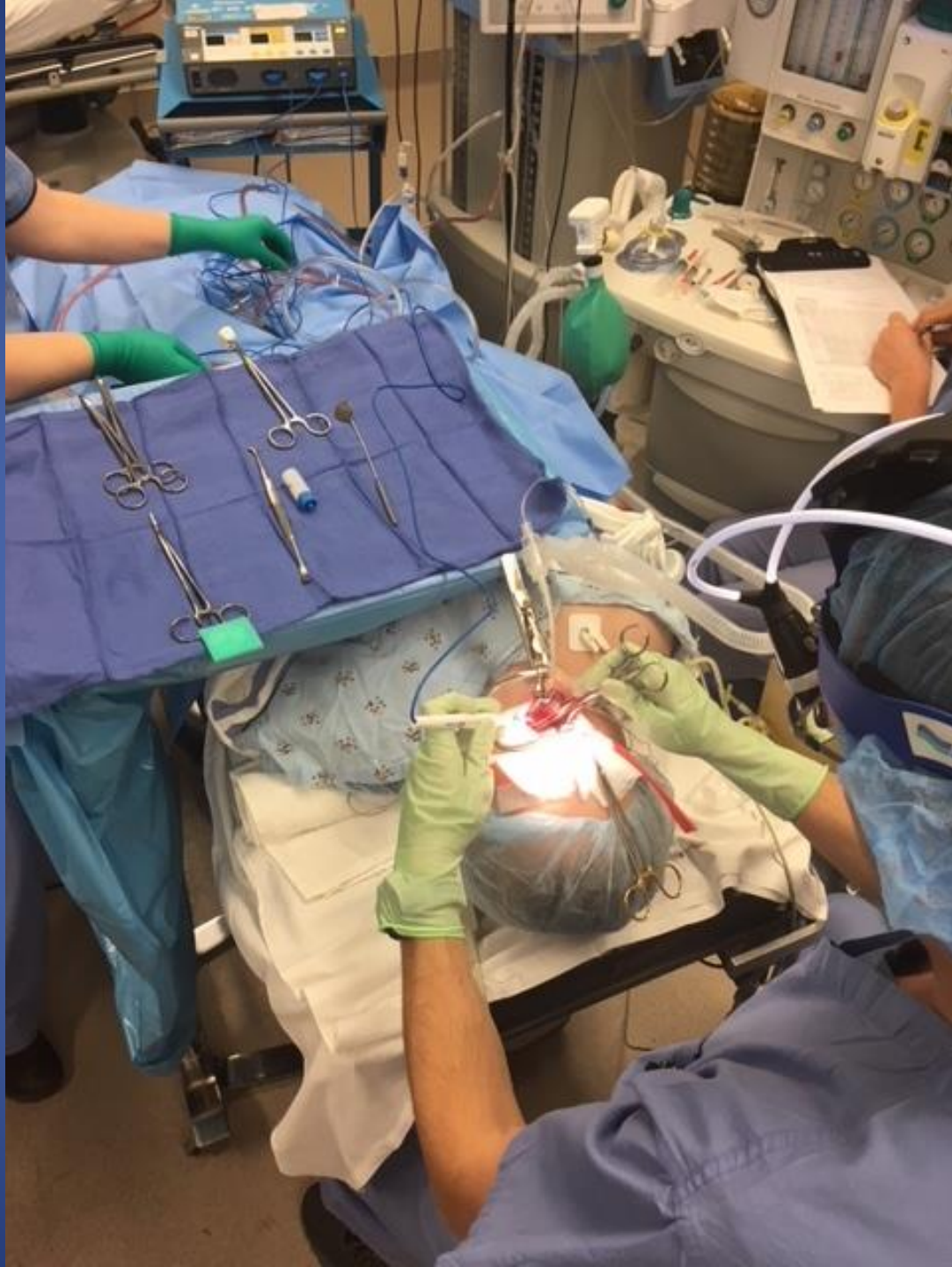- **Focused sleep history**
 - Ask about nighttime bed wetting, school performance, restless sleeping, apnea
 - Ask parents to video child sleeping
- **Polysomnogram** Gold standard for diagnosis, but not required.
 - Obesity, Down's Syndrome, Neuromuscular disease
- **Physical exam:** detailed exam of oropharynx

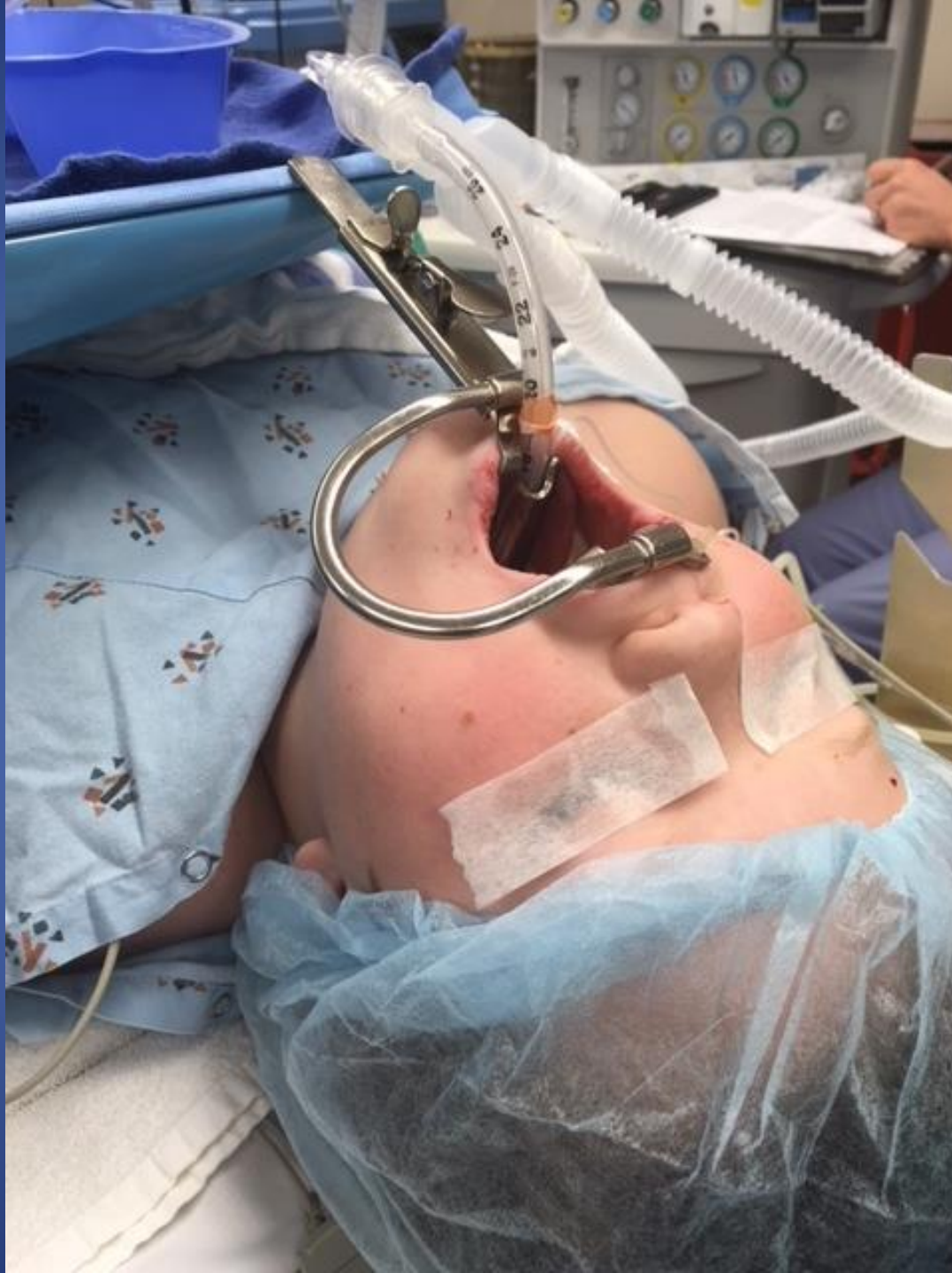

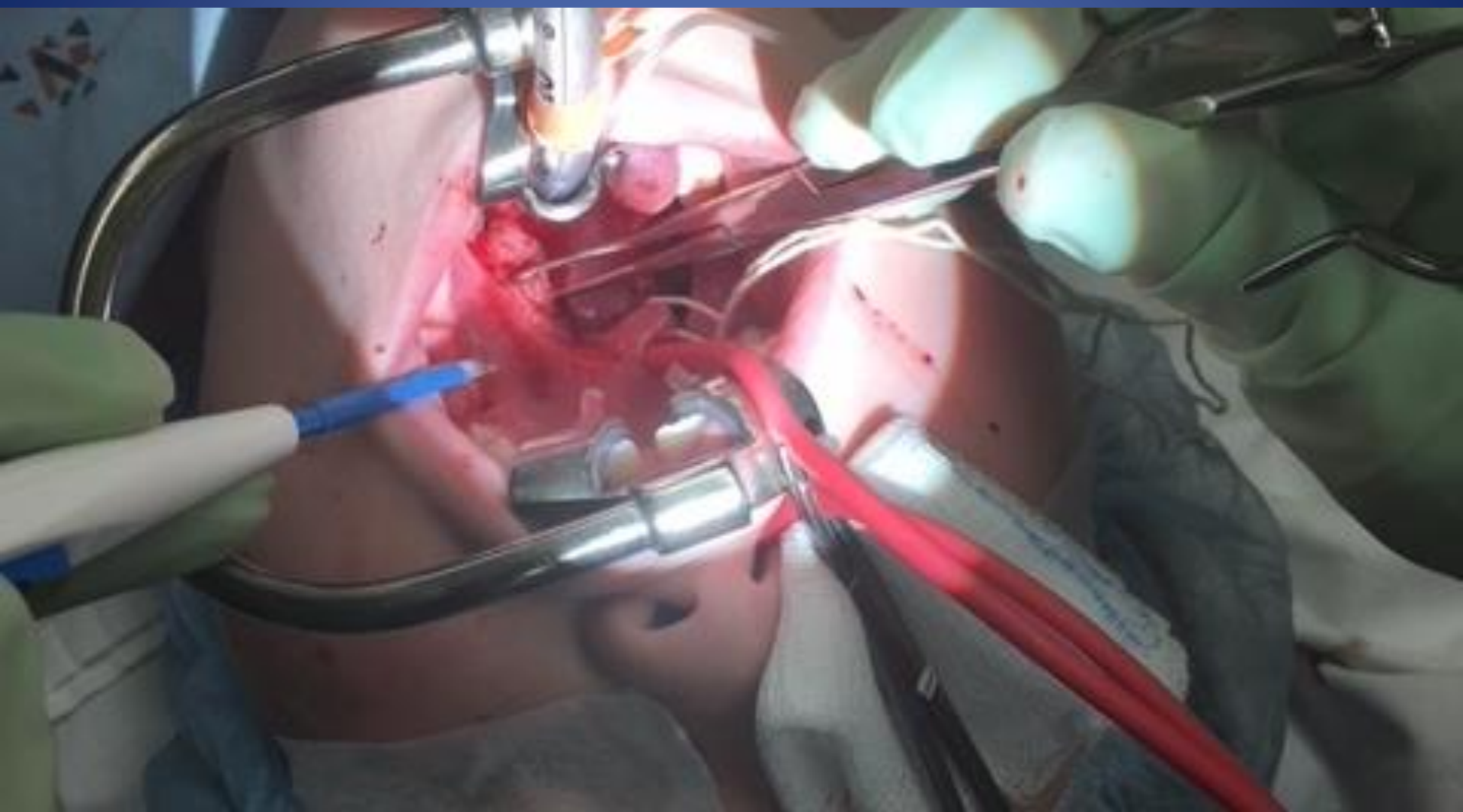



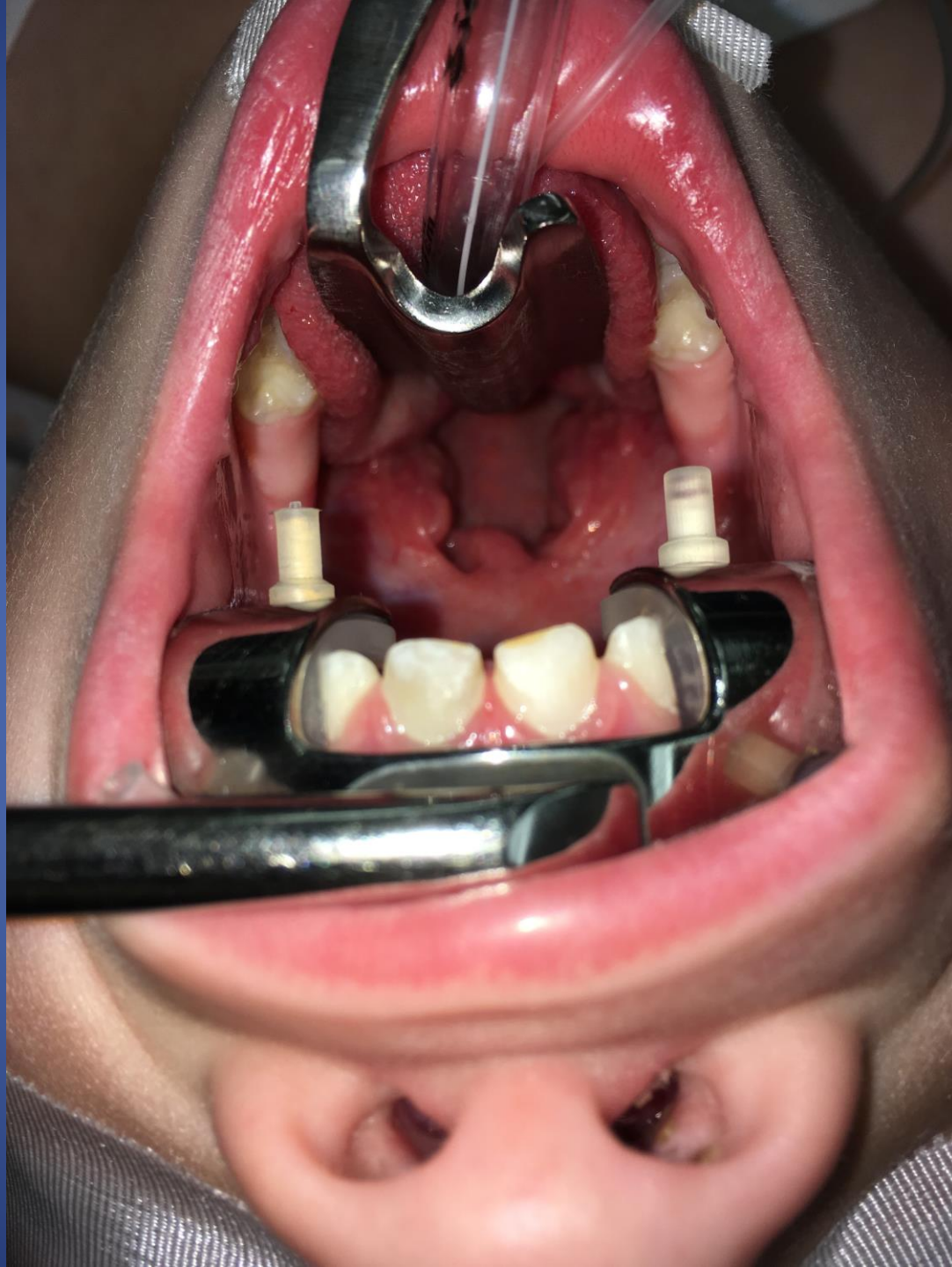
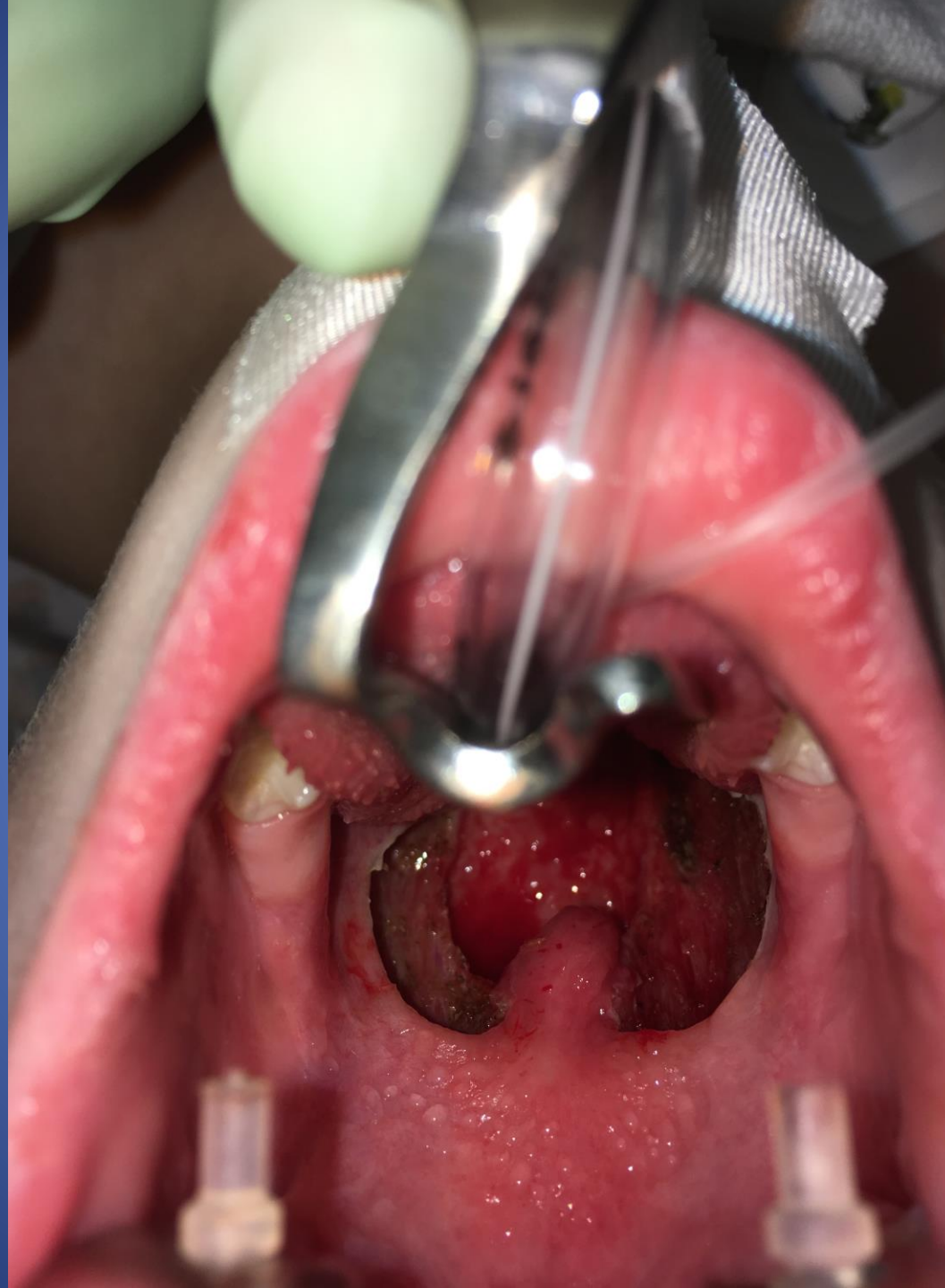




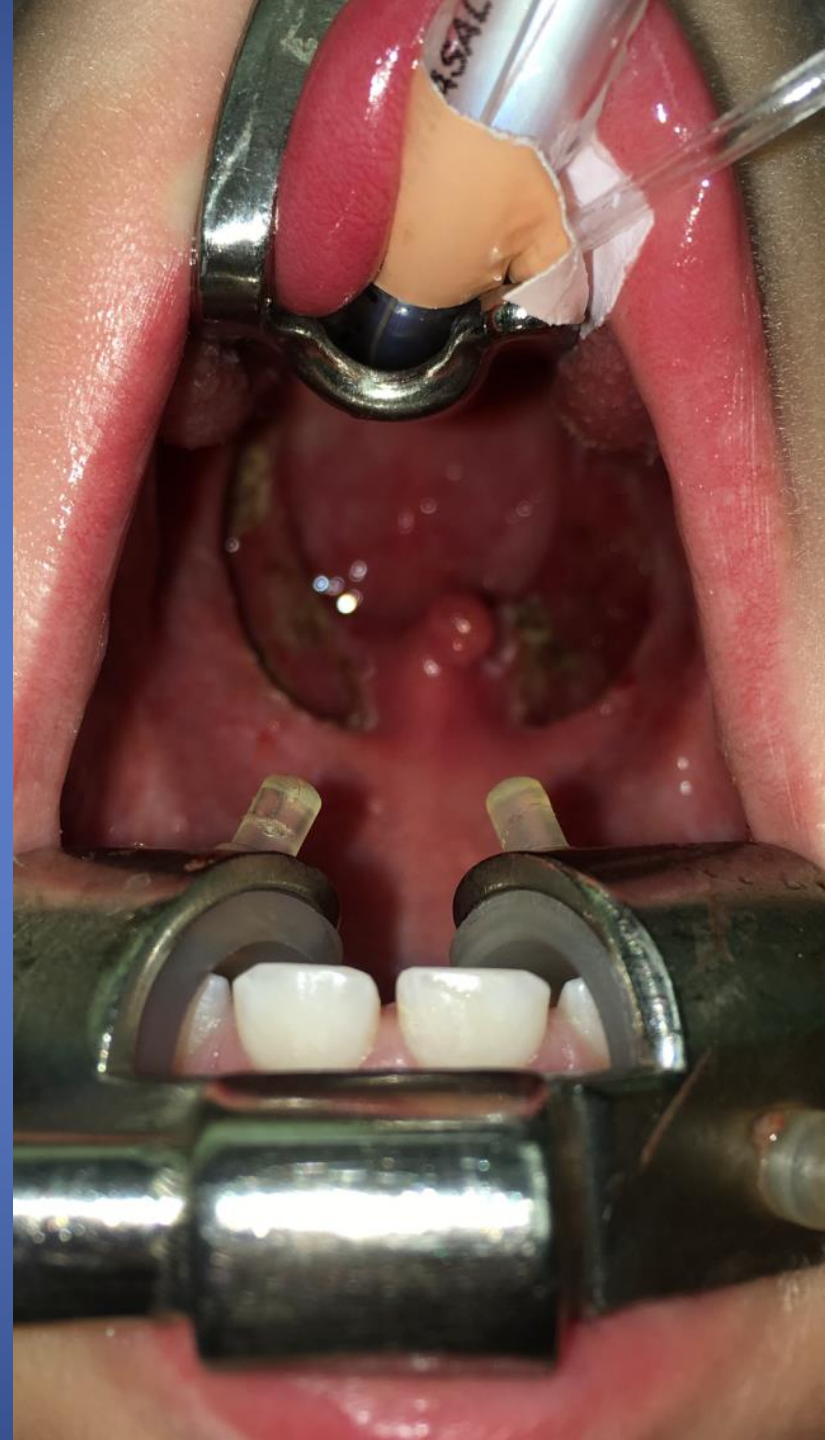
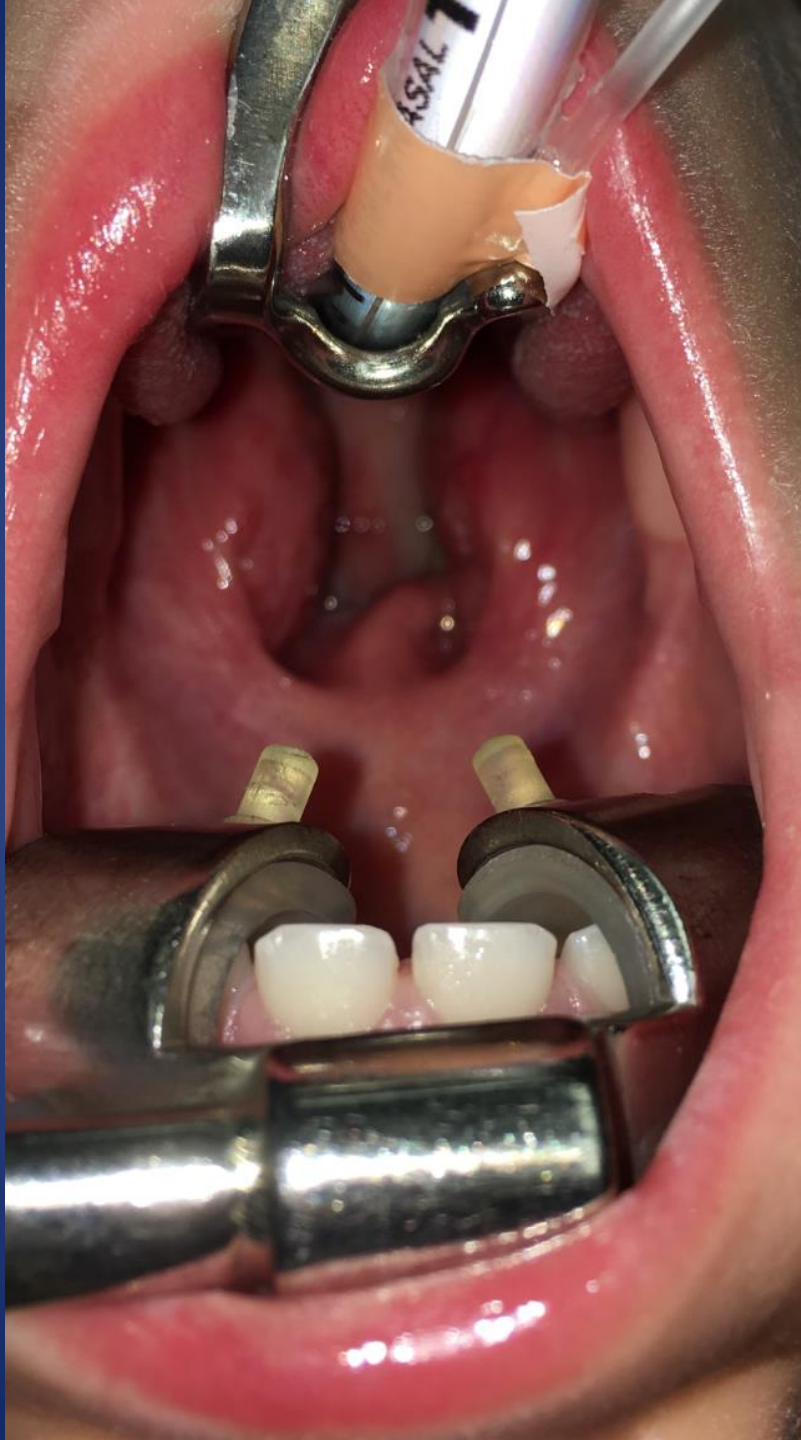


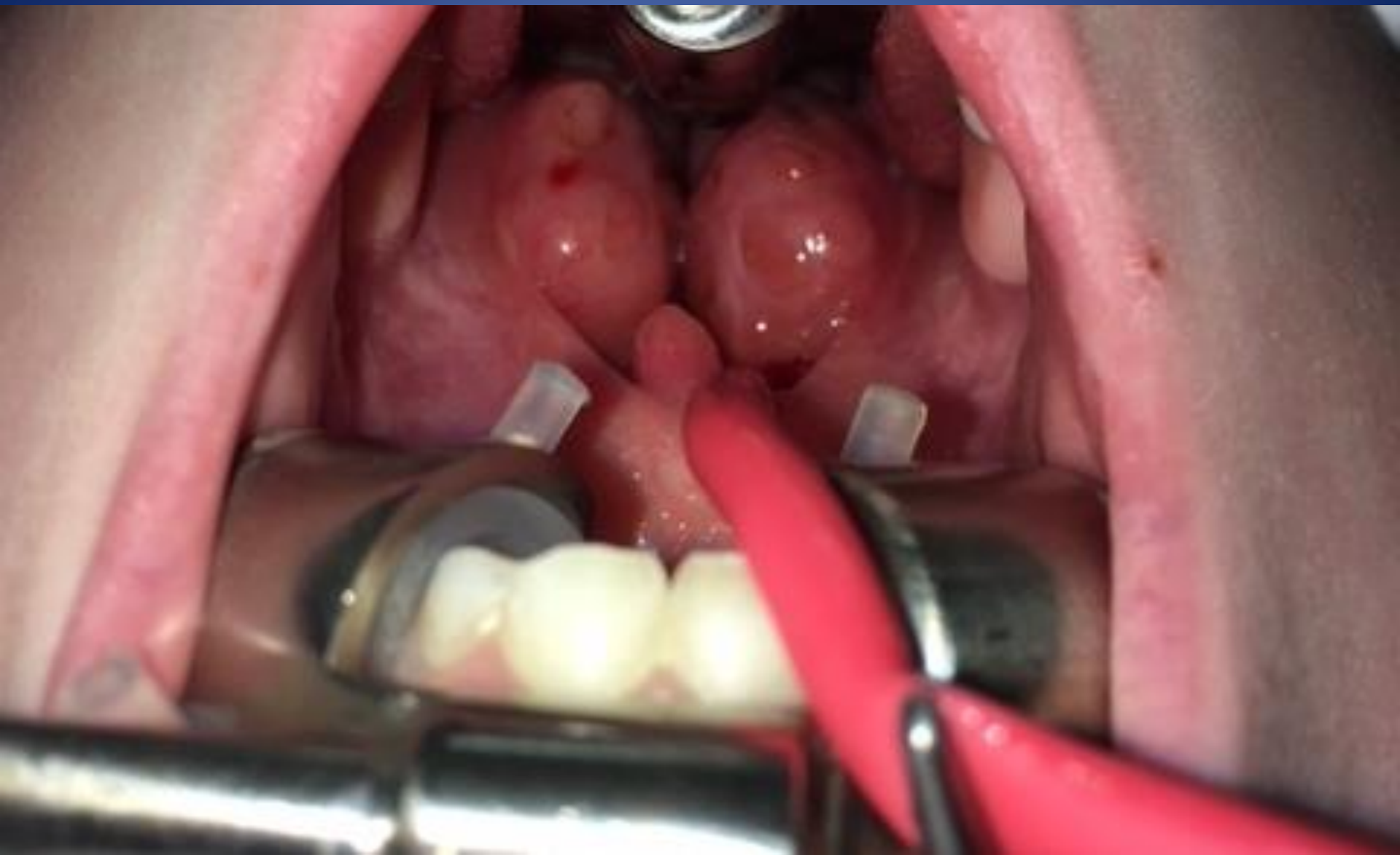


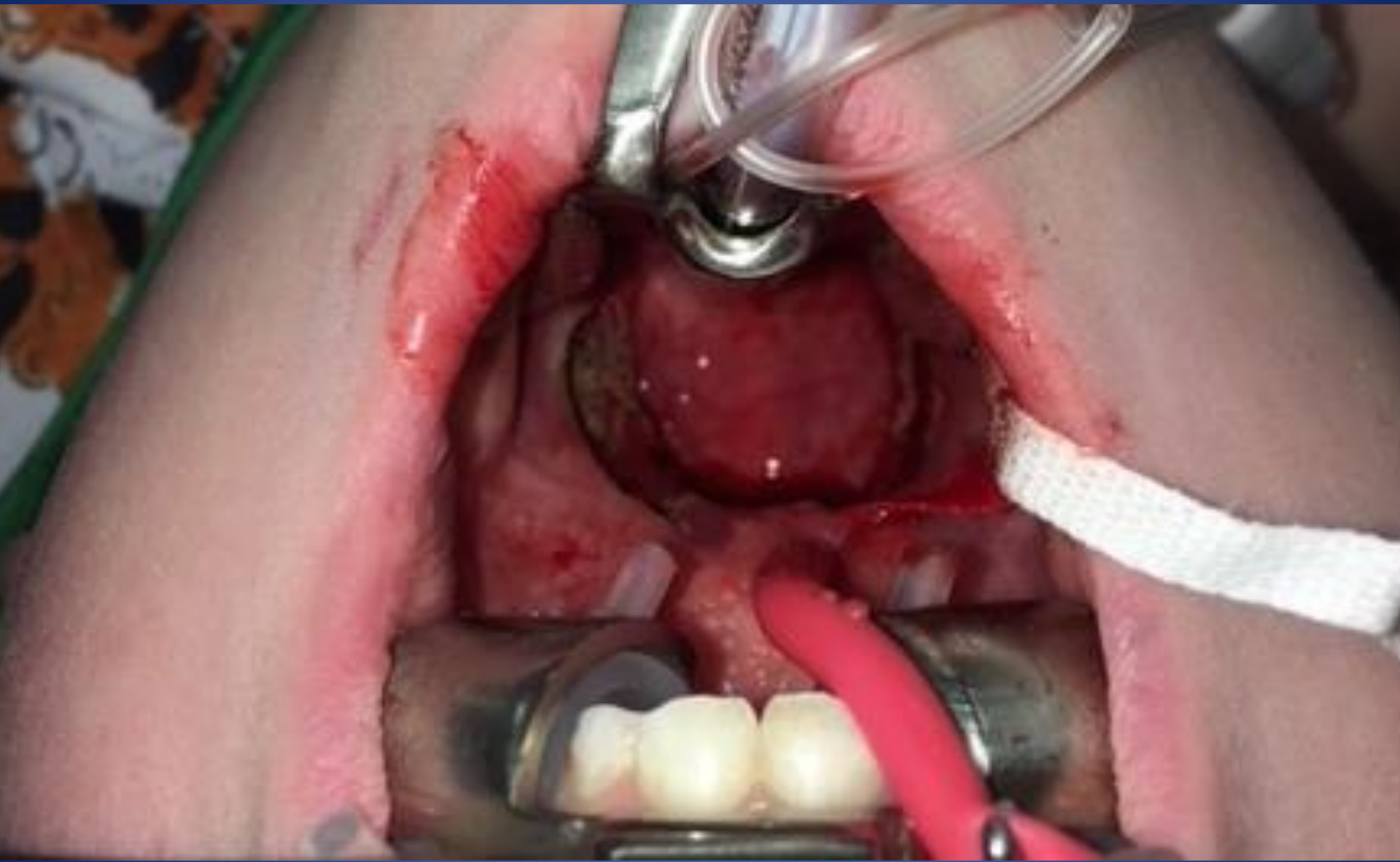






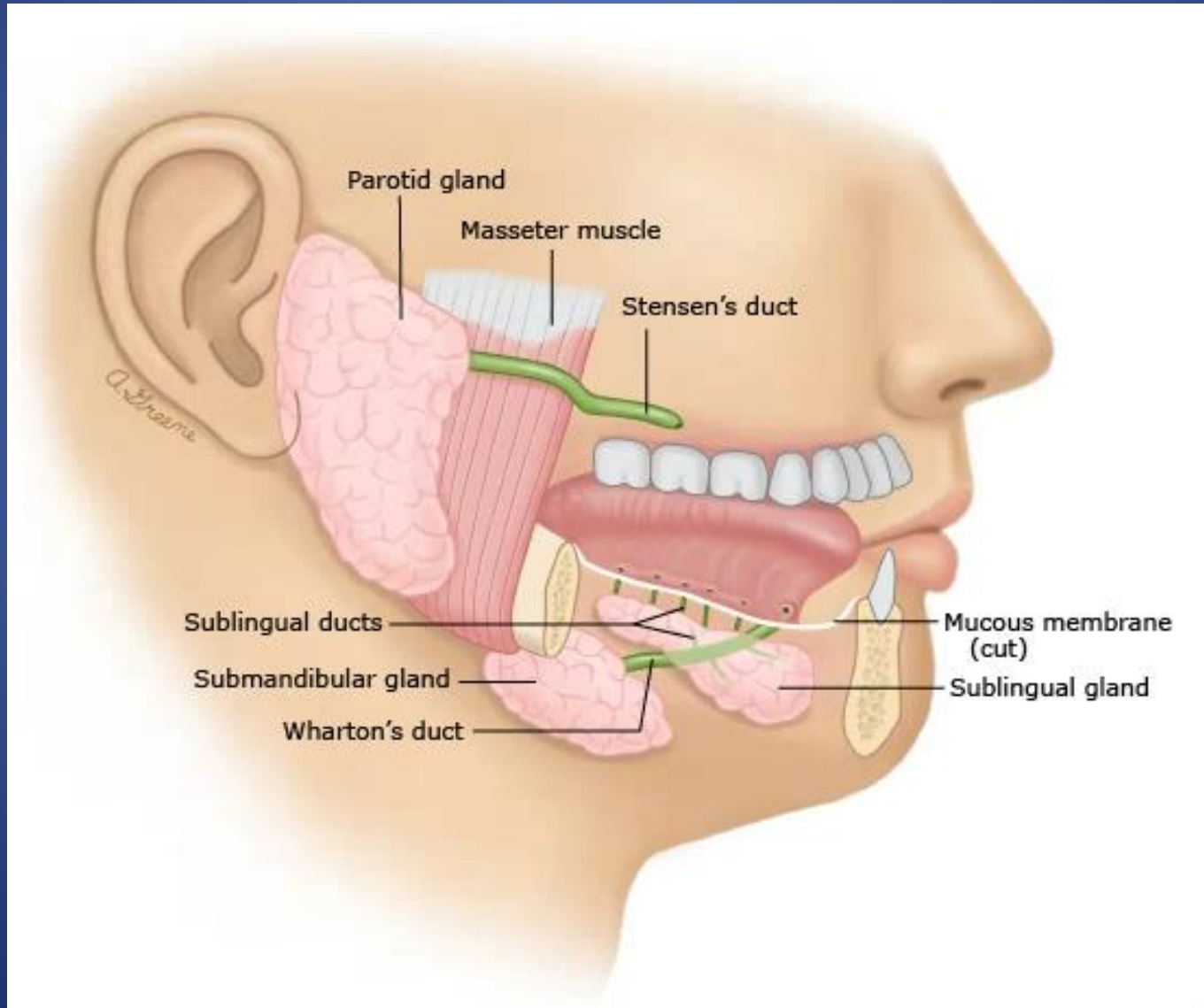
Tonsils and Adenoids: **When to Refer**

- Recurrent Adenotonsillitis
 - 7 infx/ year, 5 infx/year x 2yr, 3 infx/yr x 3yr
- Chronic Tonsillitis
 - Halitosis, tonsilloliths, strep carrier
- Peritonsillar abscess unresponsive to abx
- Tonsillar hypertrophy with SBD
- Asymmetric tonsil (usually benign)
 - Peds: Lymphoma
 - Adult: SCCA, Lymphoma

Salivary Gland disorders

- **Sialolithiasis:** Stones within the glands or ducts
- **Sialoadenitis:** Inflammation of the gland
 - *Acute:* Primary viral or bacterial infection
 - *Chronic:* Repeated episodes resulting in loss of function
- Sialolithiasis often causes Sialoadenitis

Salivary Gland Anatomy



Sialolithiasis

- Stagnation of salivary flow and calcium concentration are responsible
- SMG > Parotid
- M > F
- Risk Factors
 - Dehydration
 - Diuretics, Anticholinergic medications
 - Trauma
 - Gout
 - Smoking
 - History of nephrolithiasis

Sialolithiasis

- **Submandibular Gland**
 - 80-90% stones occur in the SMG
 - Tend to be larger
 - Most often located in the duct
- **Parotid Gland**
 - 10-20% stones occur in the parotid gland
 - Smaller stones and can be multiple
 - 1/2 are found in the gland

Sialolithiasis: Symptoms

- Pain and swelling of involved gland
- Aggravated by eating
- Can be found incidentally on radiograph
- Worsening pain, erythema and fever may indicate secondary infection (sialoadenitis)

Sialoadenitis

- **Viral Sialoadenitis:**
 - Viral parotitis due to mumps
 - Acute pain of one or both parotid glands
 - Other: Coxsackie A and B, EBV, Influenza A
- **Acute Bacterial Sialoadenitis:**
 - Older patients, Malnourished, Post-op pts
 - Parotid gland most common
 - Sudden onset of very firm and tender gland
 - Fever/chills and signs of systemic toxicity
 - Staph aureus is most common

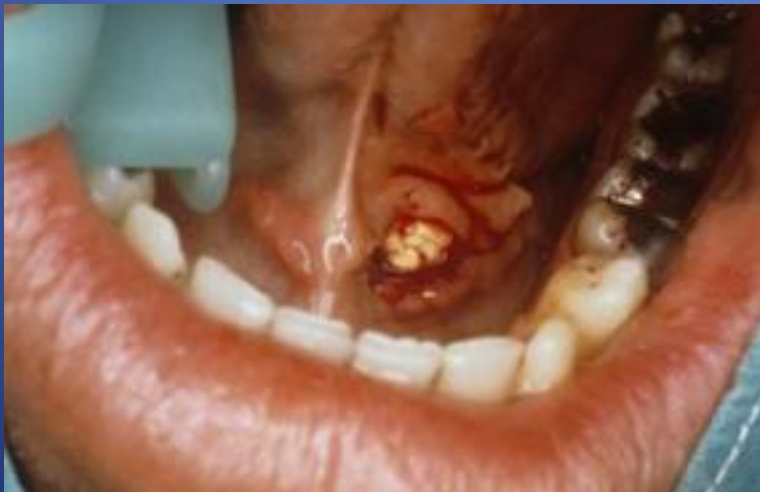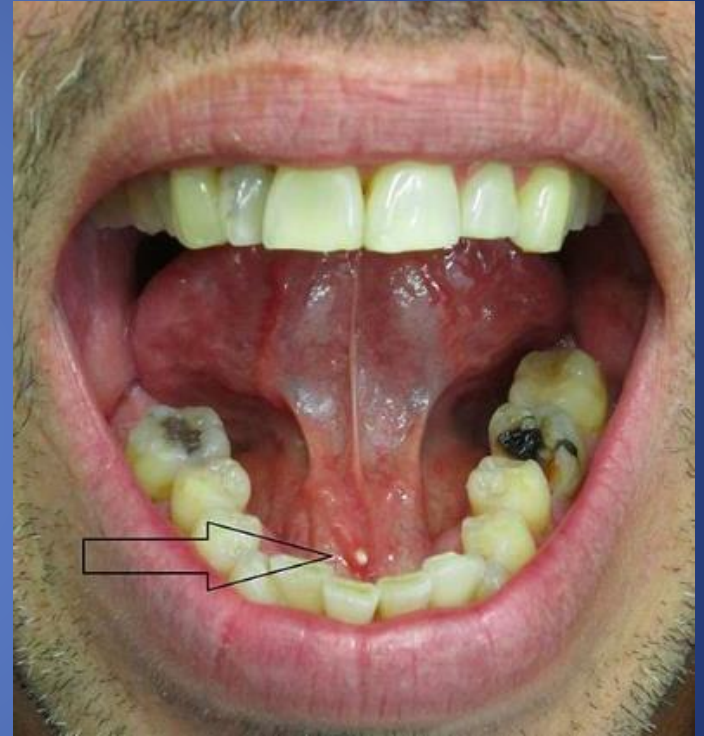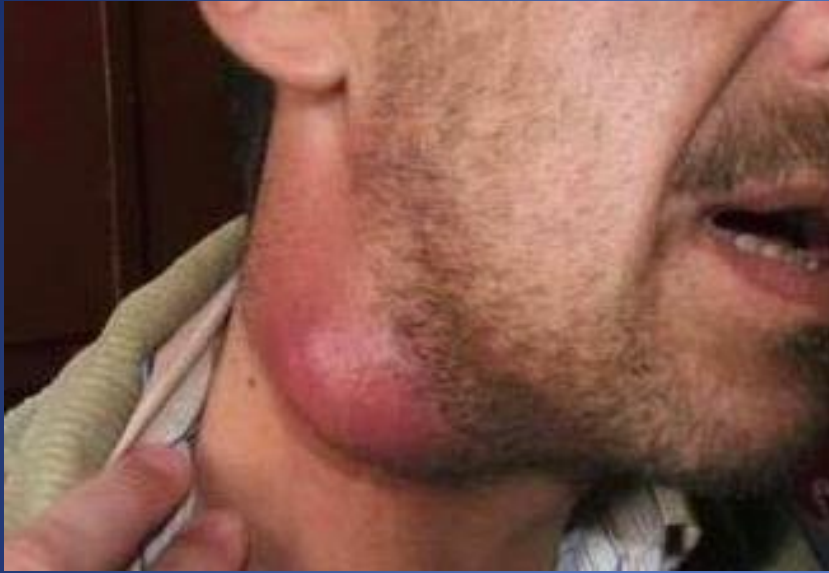Sialoadenitis

- **Chronic Bacterial Sialoadenitis:**
 - Low-grade infection, can lead to dysfunctional gland
 - Due to trauma, duct stricture, stones
- **Sjogren's syndrome:**
 - Chronic inflammatory disorder
 - Diminished lacrimal and salivary secretions
 - “Dry eyes, Dry mouth”
 - Presents as gradual swelling of glands

Sialoadenitis

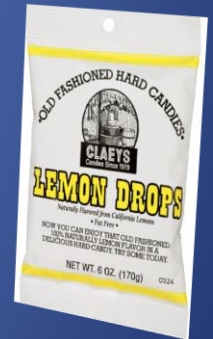- **Radiation Sialoadenitis:**
 - External beam radiation (H&N cancer pts)
 - Radioactive Iodine
 - Acute, painful glands
 - Burning, dry mouth and diminished taste

Salivary Gland: Exam



Salivary Gland: Treatment

- **Sialolithiasis:**
 - Conservative management is mainstay
 - Keep Hydrated
 - Apply moist heat
 - Massage “milk” affected gland
 - Sialogogues (lemon drops, pickles, etc)
 - Discontinue “drying meds”

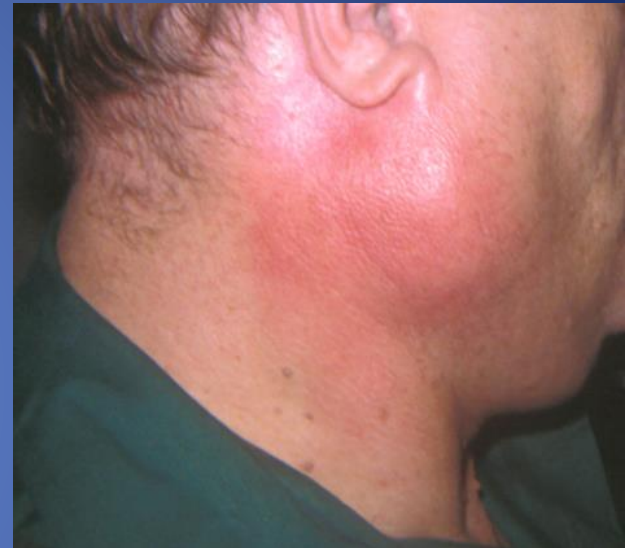

Salivary Gland: Treatment

- **Sialoadenitis:**
 - Address any underlying conditions
 - Hydration is key
 - Antibiotics for bacterial etiology (staph)
 - uptodate
- **Suppurative Parotitis**
 - Potentially life threatening infection of parotid gland

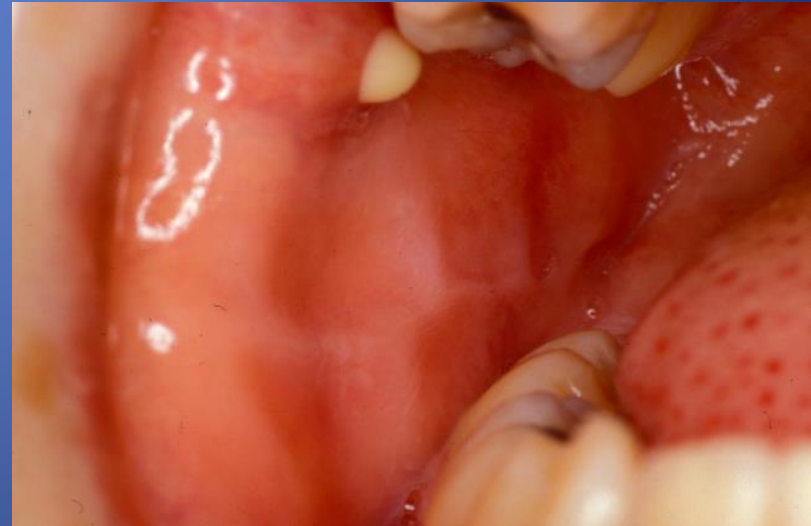Acute Bacterial Suppurative Parotitis

- Acute infection of parotid gland
- Typically seen in:
 - Elderly
 - Debilitated
 - Dehydrated (post-op)
- Salivary stasis permits retrograde seeding
- Abscess formation may occur
- Other complications:
 - Massive neck swelling with Airway compromise
 - Septicemia



Acute Bacterial Suppurative Parotitis

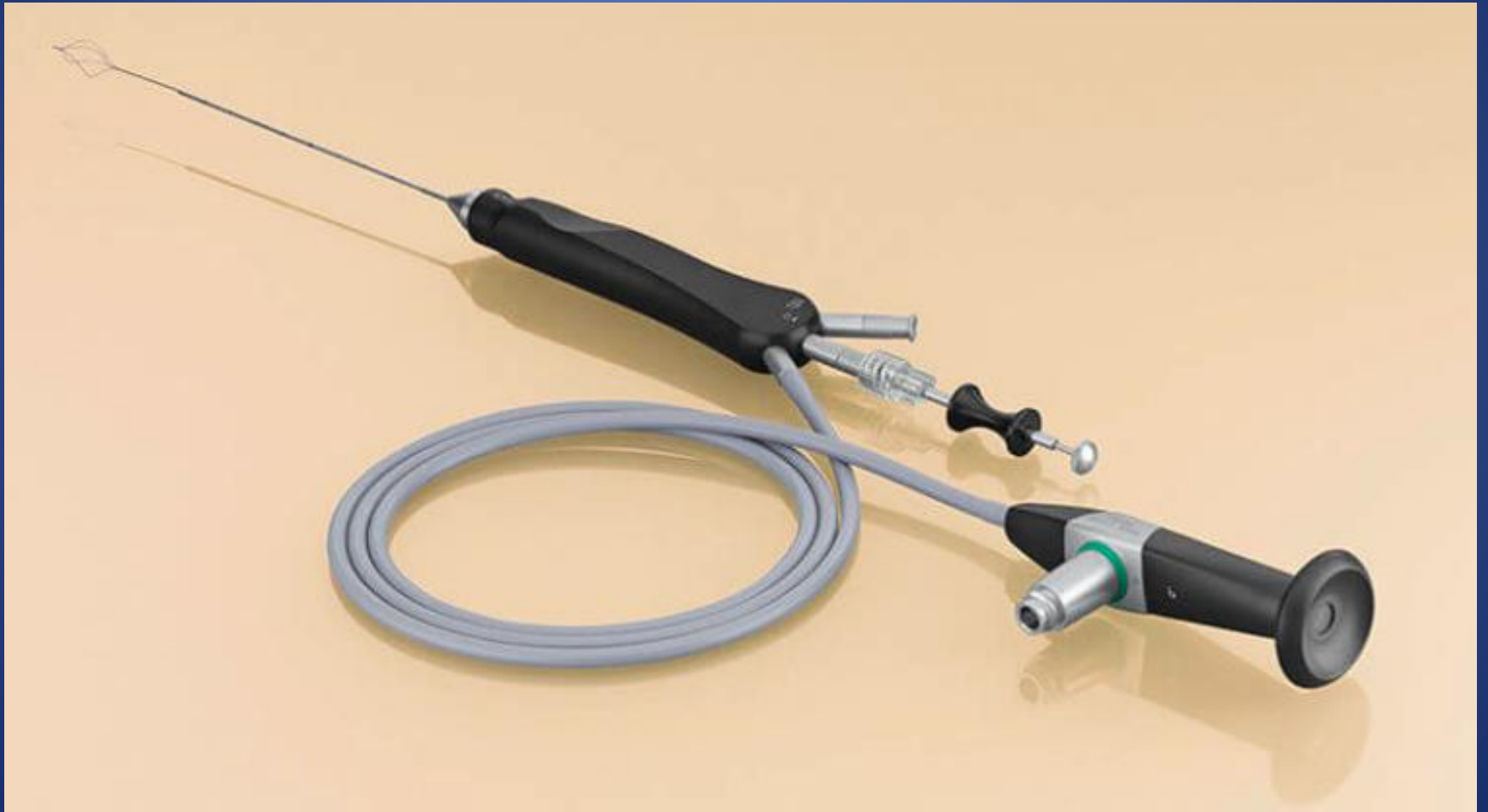- Staph Aureus is most common
- Anaerobes also common
- Infection may spread to deep fascial spaces
- CT imaging recommended
- **Treatment:**
 - IV abx and Hydration
 - Outpt treatment not advised
 - Obtain cultures if possible
 - Early consult recommended
 - I & D of abscess
 - Take to OR for gland milking

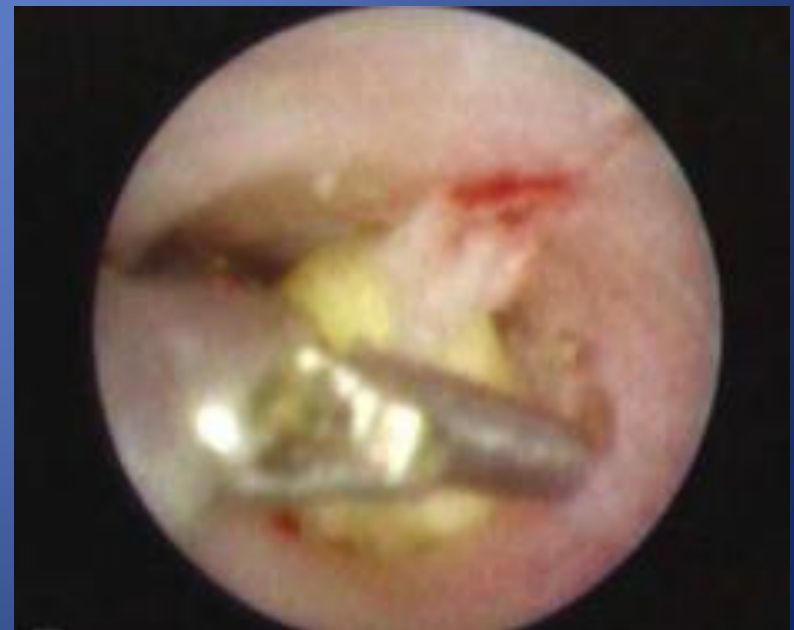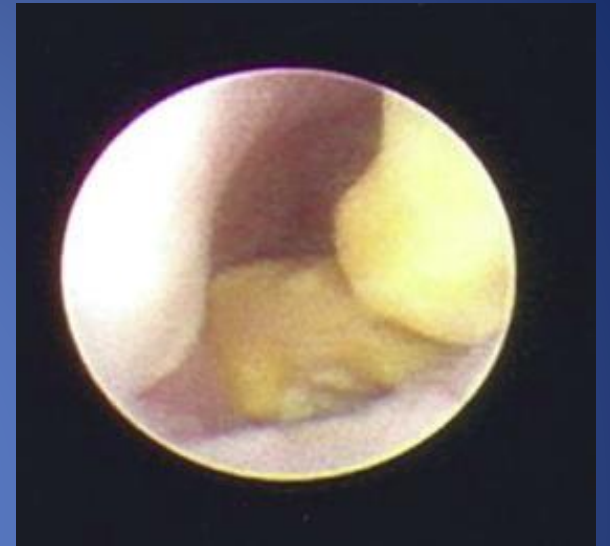

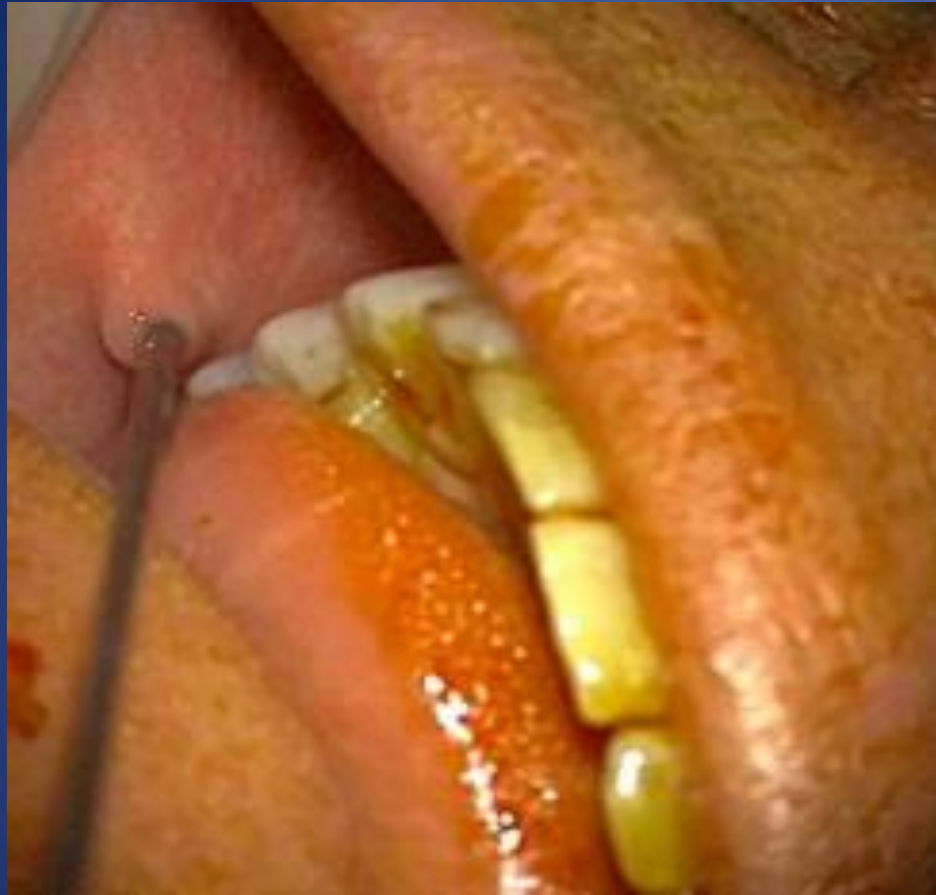
Sialoendoscopy

- Minimally invasive
- Introduced in early 1990's
- Utilizes sialoendoscopes with working channels for instrumentation
 - Wire baskets, forceps
- Effective for stone removal (<3-4mm)
- Can be used to assess duct for stenosis
- Injection of Kenalog is effective for chronic sialoadenitis

Sialoendoscopy



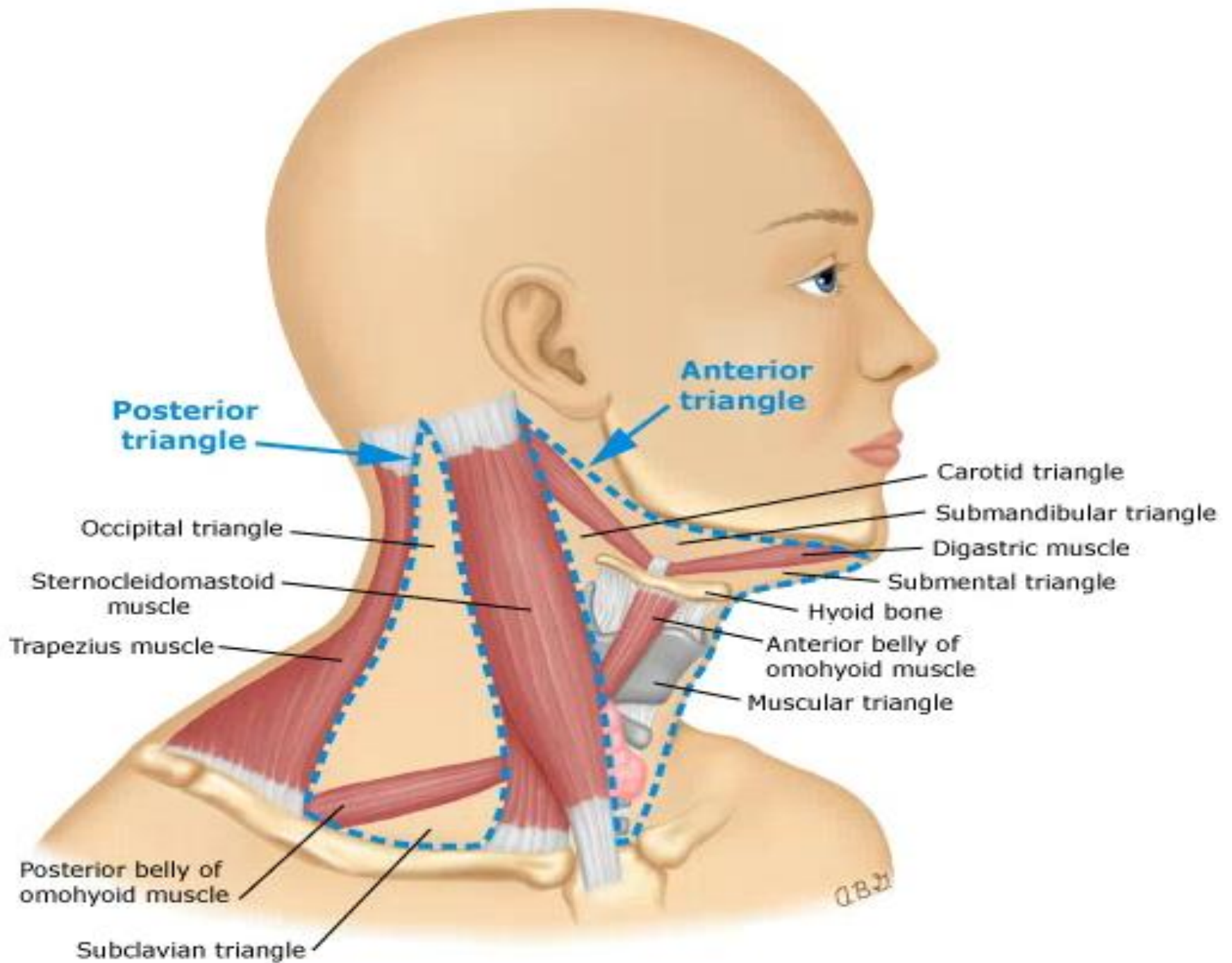


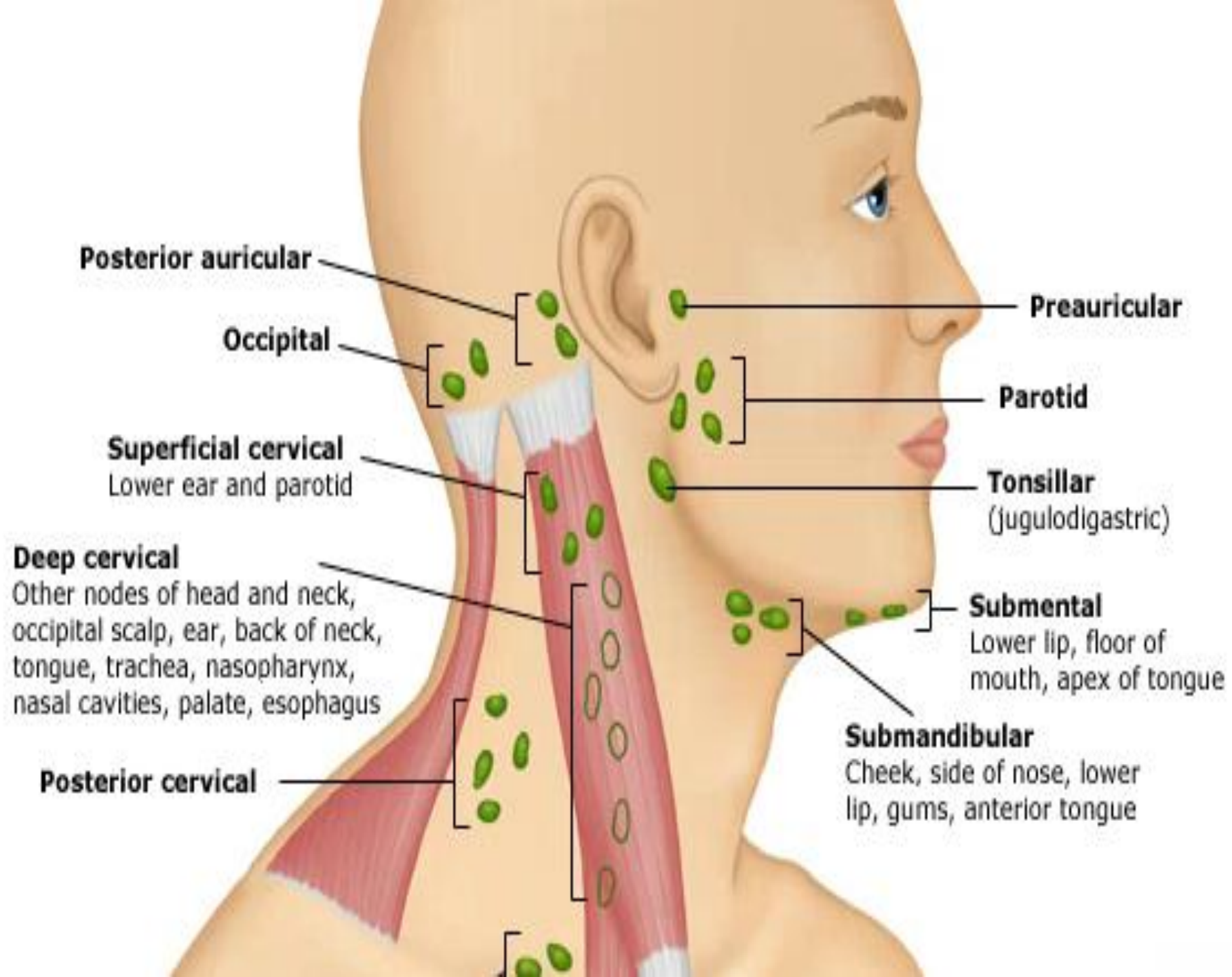
Salivary Gland: When to Refer

- **Sialolithiasis**
 - When conservative measures fail
 - If secondary sialoadenitis occurs
- **Sialoadenitis**
 - Suppurative Parotitis
 - Obtain cultures if possible
 - Order CT neck with contrast
 - Parotid/Submandibular gland abscess
- **Salivary Gland mass**
 - Order CT neck with contrast
 - Order US guided FNA

Adult Neck Mass

- Relatively common presenting complaint in primary care
- Often no associated symptoms
- Noticed it “while shaving”
- May be only manifestation of serious pathology





Posterior auricular

Occipital

Superficial cervical

Lower ear and parotid

Deep cervical

Other nodes of head and neck, occipital scalp, ear, back of neck, tongue, trachea, nasopharynx, nasal cavities, palate, esophagus

Posterior cervical

Preauricular

Parotid

Tonsillar

(jugulodigastric)

Submental

Lower lip, floor of mouth, apex of tongue

Submandibular

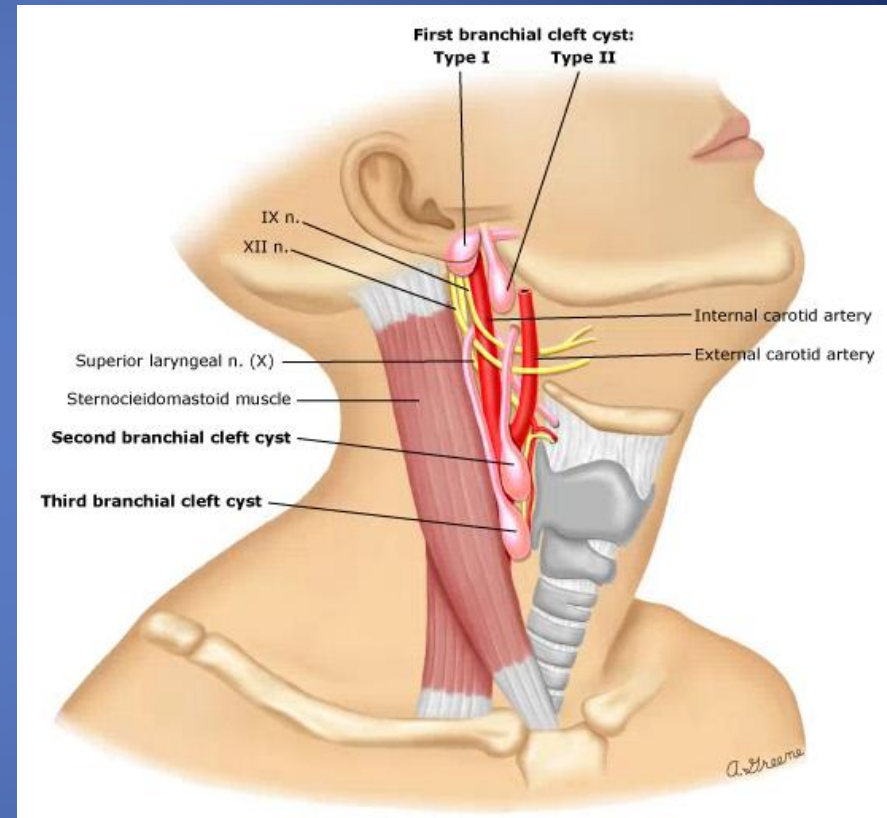
Cheek, side of nose, lower lip, gums, anterior tongue

Neck Mass: Differential Diagnosis

- **Congenital:**
 - Branchial Cleft Cyst
 - Thyroglossal Duct Cyst
 - Dermoid Cyst
 - Thymic Cysts
- **Inflammatory:**
 - Reactive Viral or Bacterial Adenopathy
- **Neoplastic:**
 - Metastatic Head and Neck Carcinoma
 - Thyroid Masses
 - Salivary Gland neoplasms
 - Paragangliomas
 - Lymphoma

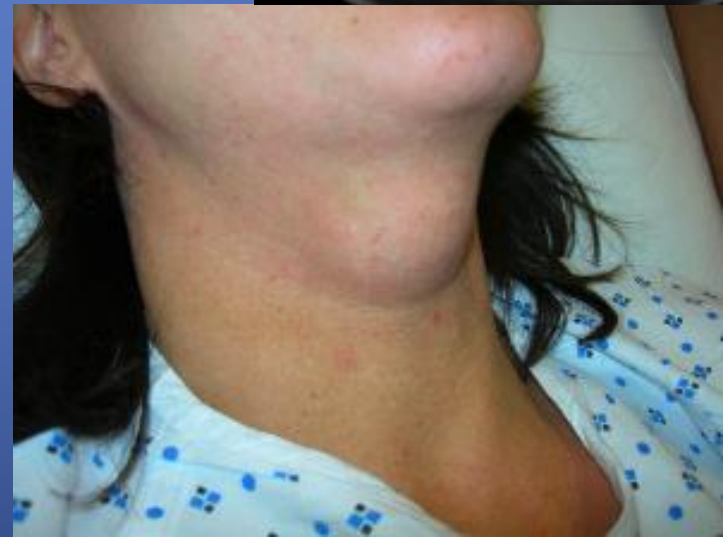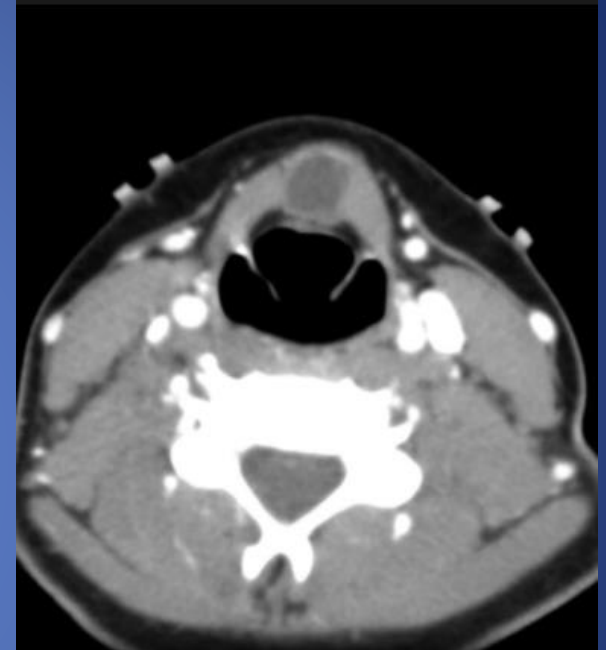Congenital Neck Mass: Branchial Cleft Cyst

- Usually present in childhood
- Can be seen in adults
- 2nd branchial cleft cyst is most common
 - Located anterior to SCM
- “Cystic” in nature



Congenital Neck Mass: Thyroglossal Duct Cyst

- Midline neck mass
- Asymptomatic
- May become infected
- 40% present >20 yo
- 1-2% can be malignant



Inflammatory Neck Mass

- **Reactive Viral Lymphadenopathy**
 - Most common cause of cervical adenopathy
 - Due to upper respiratory viral infection
 - Usually resolves within 2 weeks of symptom resolution
- **Bacterial Lymphadenopathy**
 - Results from infections in oropharynx or skin
 - Staph aureus and Group B Strep
 - Can lead to neck abscess formation
 - Initial Antibiotic therapy usually effective, may require I&D

Neoplastic Neck Mass

- **Metastatic Head and Neck Cancer**
 - SCCA from the upper Aerodigestive tract
 - ALWAYS consider this as diagnosis
 - Usually asymptomatic
 - Oropharynx, Nasopharynx, Skin/Scalp
 - Diagnosis confirmed with FNA
- **Thyroid Mass**
 - Most thyroid nodules are benign
 - Papillary thyroid cancer is most common
 - Rapid growth: Anaplastic carcinoma and Lymphoma
- **Salivary Gland Neoplasm:**
 - “80%” Rule (Parotid Gland, Benign)
 - Pleomorphic Adenoma is most common
 - Submandibular gland masses: 50% malignant

Adult Neck Mass: History

- **Age**
 - <16: inflammatory or congenital
 - 16-40: increased frequency of malignancy
 - >40: Considered neoplastic until proven otherwise
- **Growth pattern:**
 - Present for years or fluctuate in size are typically benign
 - Rapidly enlarging raises concern
- **Symptoms**
 - Pain = related to rate of growth and expansion
 - “B” symptoms: Fever, Night sweats, weight loss

Adult Neck Mass: Location

- **Preauricular/Angle of Jaw:**
 - Likely represents salivary or lymphoid tissue
- **Central Neck:**
 - Mass is usually thyroid in origin
- **Anterior/Superior aspect of SCM:**
 - Common site for enlarged malignant node
 - (Think Oropharyngeal Carcinoma)
 - Common location for Branchial Cleft Cyst
- **Posterior Triangle:**
 - High index of suspicion
 - Nasopharyngeal carcinoma presentation
- **Supraclavicular fossae:**
 - Metastasis from below clavicle (lung, GI, Renal)
 - Common location for lymphoma

Adult Neck Mass: Exam

- **Mass Characteristics:**
 - Location, Size, Consistency, Tenderness, Mobility
- Discrete, mobile, firm node = **Reactive node**
- Rock Hard, fixed and/or matted = **Malignancy**
- Soft, ballotable, mobile = **Congenital cyst**
- Pulsatile mass or bruit = **Vascular lesion**

Adult Neck Mass: Exam

- Thorough exam of the Head and Neck
 - Oral cavity and Oropharynx
 - Bimanual palpation of FOM and tongue
 - Examine skin and scalp for suspicious lesions
 - Assessment of cranial nerves
 - Thyroid exam

Adult Neck Mass: **Workup**

- **Labs**
 - CBC, ESR, EBV, HIV (if at risk)
- **Imaging studies:**
 - Ultrasound:
 - non-invasive, inexpensive, no radiation
 - Preferred for thyroid eval, younger, low risk pts
 - CT scan:
 - BEST study for suspicious masses
 - ALWAYS use contrast (unless kidney disease, etc)
 - MRI:
 - Excellent soft tissue differentiation
 - Evaluate perineural spread, parapharyngeal space masses

Adult Neck Mass: Biopsy

- **Fine-needle Aspiration:**
 - Preferred approach for most neck masses
 - 25 or 27 gauge needle
 - Safe, accurate (90%)
 - Request US-Guided FNA (radiology department)
 - Sometimes not adequate for thyroid and lymphoma
- **Core biopsy:**
 - 14 or 18 gauge needle
 - Used if FNA non-diagnostic
- **Other:** CT Guided FNA, Open biopsy

Adult Neck Mass: Management

- Infectious neck masses promptly treated with antibiotics (Augmentin, Cleocin)
- If suspicious mass, proceed with imaging and biopsy if indicated (US, CT with contrast, FNA)

Adult Neck Mass: **When to refer**

- If antibiotic therapy fails
- If mass:
 - Has been present >2 weeks or unknown duration
 - Firm, fixed mass
 - Nodes $> 1.5\text{cm}$ is size
 - Ulceration of overlying skin
- Consider proceeding with CT and FNA prior to referral

HPV and Oropharyngeal Cancer

- Human Papillomavirus (HPV) infection:
 - Most commonly diagnosed STD
 - Has been etiologically linked to:
 - Anogenital malignancies (cervical cx, etc.)
- Now recognized as cause of HPV+ Oropharyngeal cancer
 - (Squamous Cell Carcinoma)
 - Located in the Base of Tongue and Tonsil

HPV: Biology

- Small DNA virus that is widely distributed in vertebrates
- HPV-16 is most common genotype to cause H&N cancer
 - Other subtypes include 18, 31, 33
- Patients usually lack typical risk factors for H&N cancer
 - “Sminkers”

HPV Oropharynx Cancer: Epidemiology

- Since 1980's, there has been a DECREASE:
 - Laryngeal, Hypopharyngeal and Oral cancers
 - Secondary to decrease in smoking (#1 risk factor)
- Oropharynx cancer rates have INCREASED
 - Due to HPV+ Oropharyngeal cancers
 - Studies show 50-70% of Oropharynx cancer is HPV+
- HPV Prevalence in General Population
 - Age 14-69: 6.9% (HPV 16: 1%)
 - M>F

HPV-Oropharyngeal Cancer Rates

- Annual number of HPV-related (HPV-16) **oropharyngeal cancers** is expected to exceed the annual number of **cervical cancers** in the U.S. in 10 years !!!

CLINICAL REVIEW

JABFM
JOURNAL OF THE AMERICAN BOARD OF FAMILY MEDICINE

The Growing Epidemic of HPV-Positive
Oropharyngeal Carcinoma: A Clinical Review for
Primary Care Providers

JABFM July–August 2015 Vol. 28 No. 4

HPV+ Oropharynx Cancer: **Clinical Features**

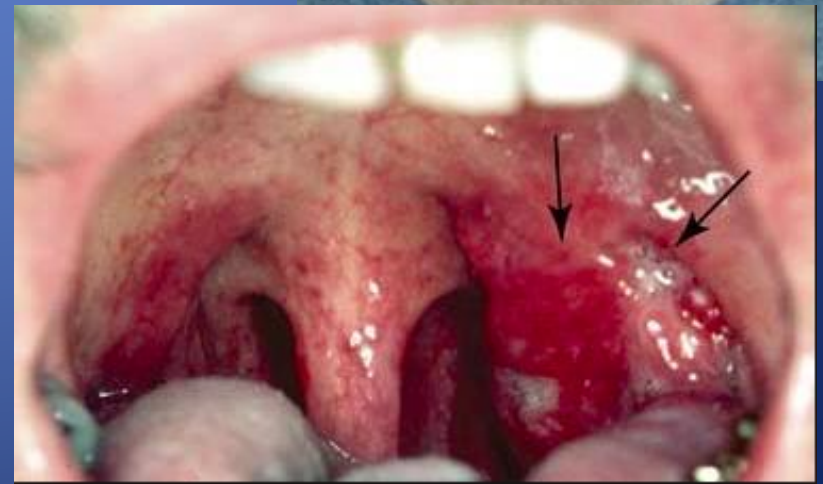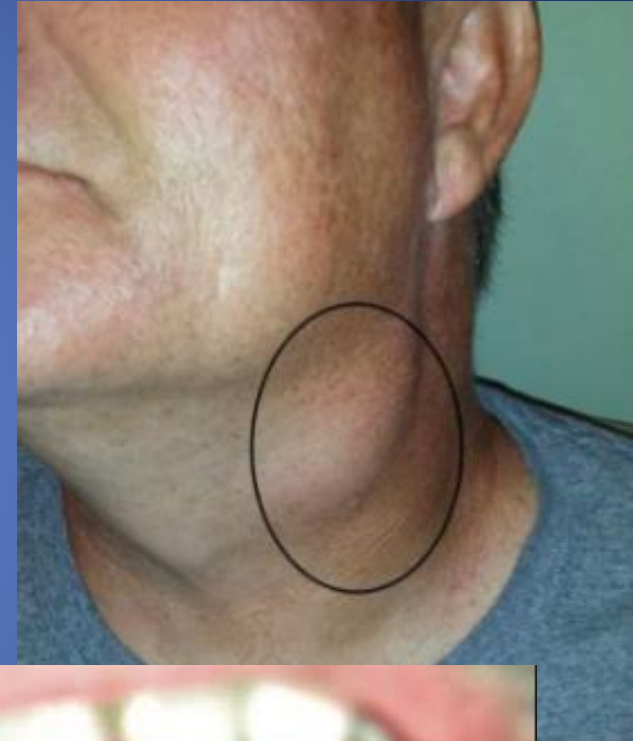- Younger Age (30-60 yo)
- Male > Female
- Non-smoker/Non-Drinker
- Better survival.
- Lower risk for second primary cancers
- Higher incidence of oral sex practice
- Higher socioeconomic status

HPV+ Oropharynx Cancer: Presentation

- Neck Mass (most common)
- Sore throat
- Dysphagia/Odynophagia
- Visualized oropharyngeal mass
- Otalgia (referred pain)

HPV+ Oropharynx Cancer: Exam

- Close inspection of tonsils
- Palpate base of tongue
- Detailed exam of cervical lymph nodes
- Level 2 node (superior Jugulodigastric) is most common location



HPV+ Oropharynx Cancer: Role of Primary Care

- Awareness of this disease process
- Early referral
- Can have significant impact on:
 - Survival outcomes
 - Quality of Life
- HIGH INDEX OF SUSPICION !
- Work-up:
 - CT neck with contrast
 - Order US-Guided FNA

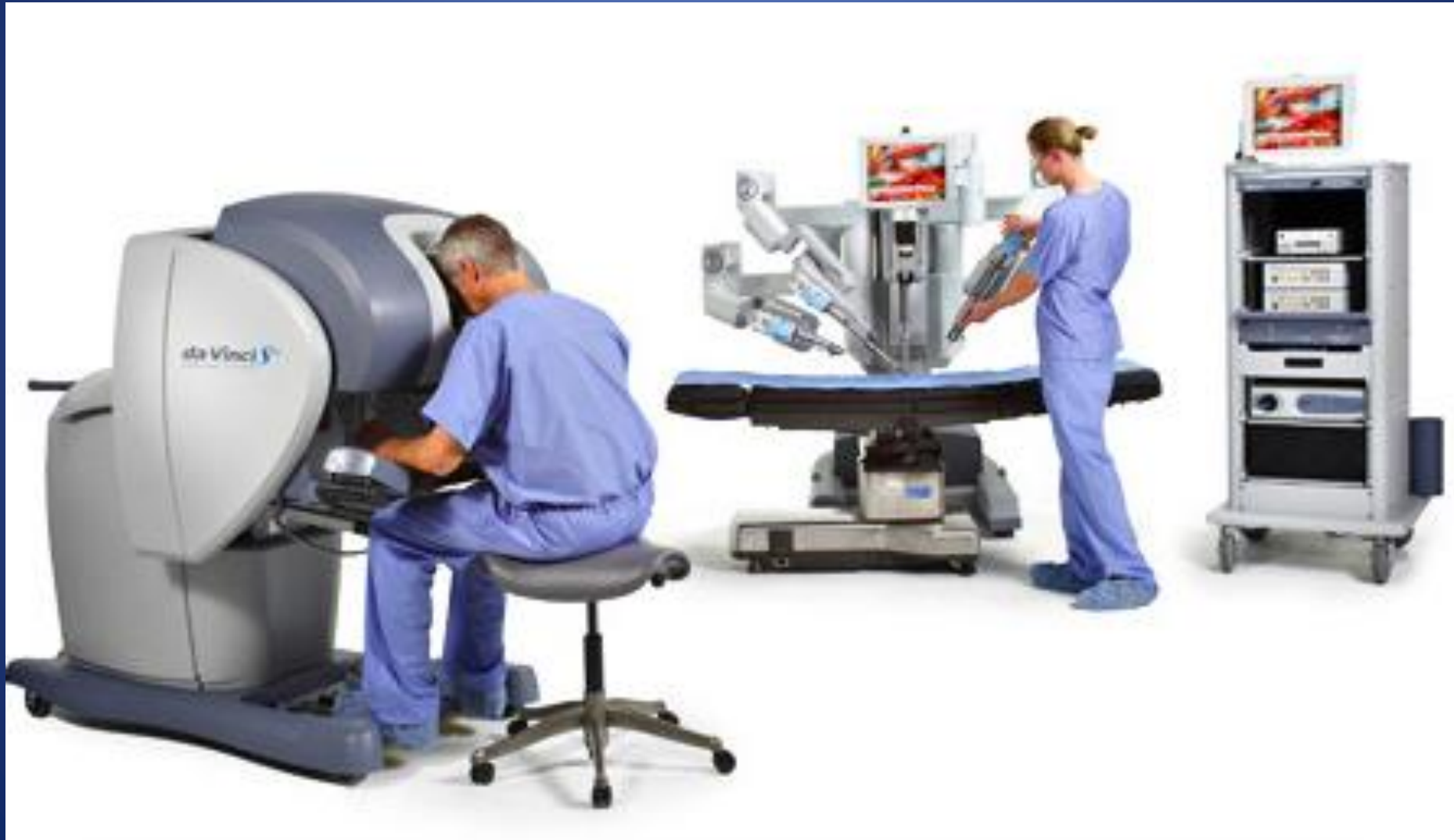HPV Vaccine

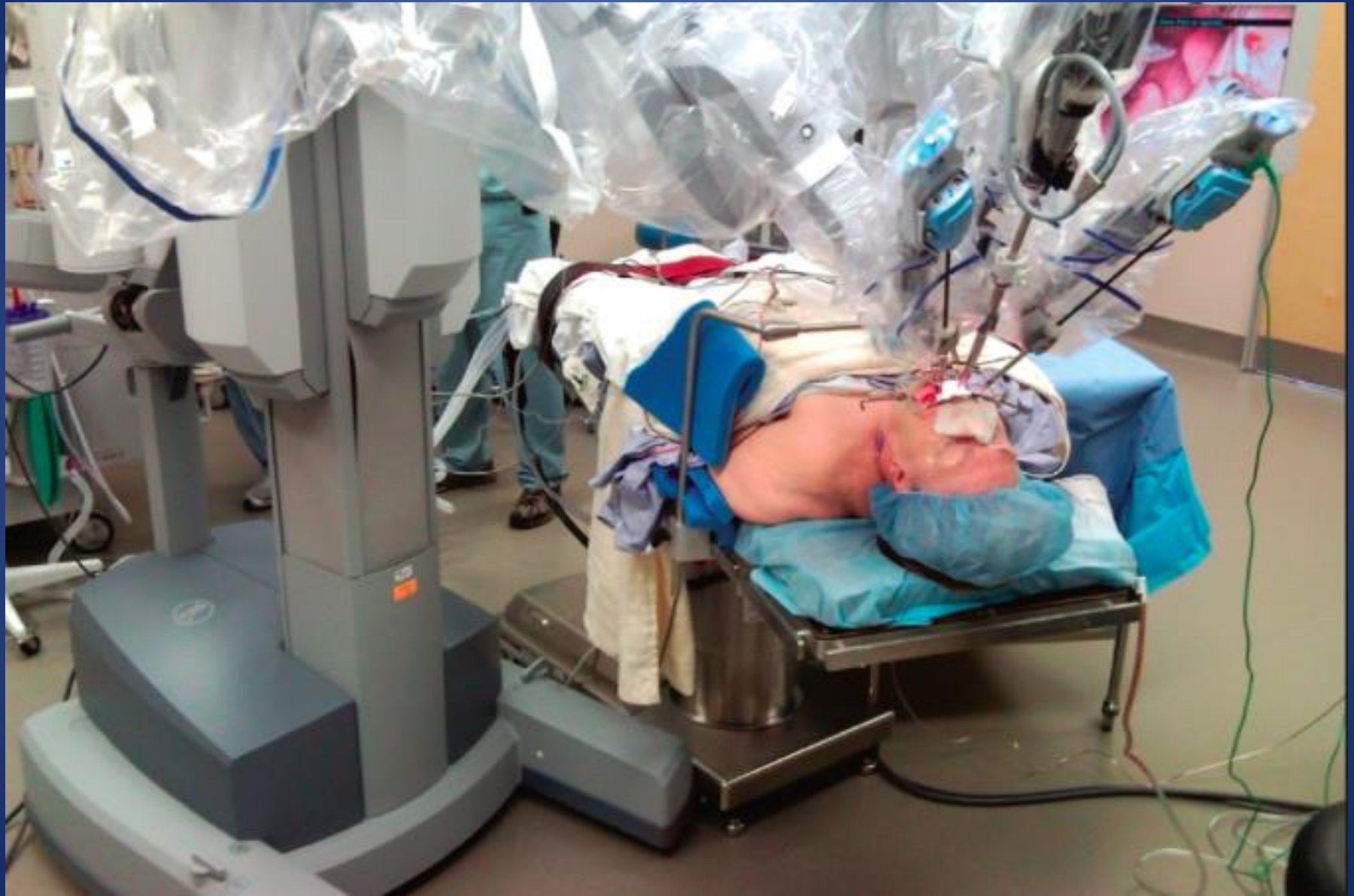- **Currently 2 Vaccines available**
 - Cervarix (targets HPV-16, 18)
 - Gardasil (targets HPV-6, 11, 16, 18)
- **CDC recommends:** 11- to 12-year-old boys and girls get two doses of HPV vaccine. The second dose should be given 6 to 12 months after the first dose.
- **CDC also recommends:** that girls and women through age 26 years and boys and men through age 21 years get the vaccine if they were not vaccinated when they were younger. Men who are 22 through 26 years old also may be vaccinated.

HPV+ Oropharynx Cancer: Treatment

- H&N Cancer can be treated with:
 - Surgery
 - XRT
 - Chemo/XRT
- Surgical Treatment for Oropharynx Cancer has evolved
- Use of Surgical Robot has revolutionized treatment

TORS (Transoral Robotic Surgery)





HPV+ Oropharyngeal Cancer: When to Refer


- Any adult male with level 2 neck mass !!
 - High index of suspicion
- Asymmetric Tonsil/Tonsil Mass
- Chronic throat pain or odynophagia

Presidents of the United States: ENT Conditions

George Washington (1789-1797)

Diagnosis: Acute Epiglottitis

- Dec 13, 1799 – Began feeling ill after horseback riding in cold weather
- Dec 14, 1799
 - **2am:** Washington woke with throat pain, fever, and trouble breathing
 - three physicians were summoned to Mt. Vernon, Virginia to see the president
 - **7:30am:**
 - Blood letting: 12-14oz
 - Given Tonic of Molasses, Butter and Vinegar



George Washington (1789-1797)

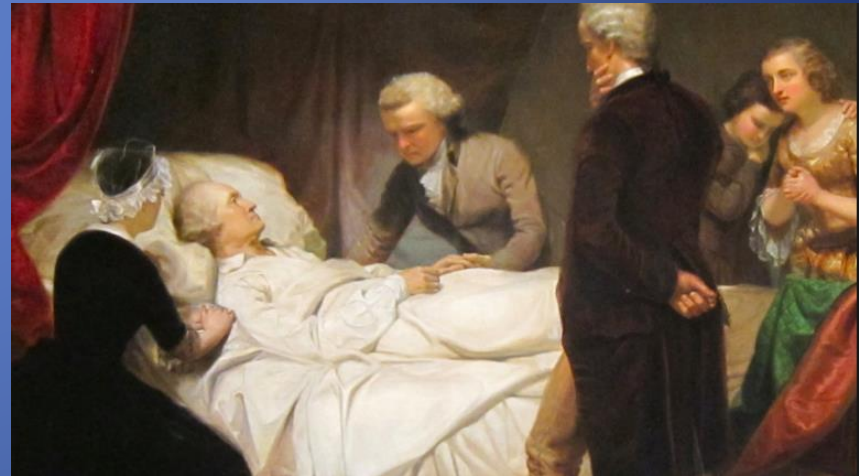
Diagnosis: Acute Epiglottitis

- 9am:
 - Dr. Craik applied a “painful blister of cantharides”
 - Tortuous treatment known for “counter-irritation”
 - Draw out the deadly humors causing the infection
- 9:30am and 11am:
 - Another 18 oz of blood letting each time
- Noon:
 - Enema, gargling with sage tea laced with vinegar

George Washington (1789-1797)

Diagnosis: Acute Epiglottitis

- 4pm:
 - Another blood letting, 32 oz
 - Dose of Mercurous Chloride and Potassium Tartrate emetic were given
 - Caused horrific vomiting
- 5pm:
 - Began struggling for air again
 - “Doctor, I die hard, but I am not afraid to go”



George Washington (1789-1797)

Diagnosis: Acute Epiglottitis

- 8pm:
 - Blisters of Cantharides applied to feet, arms and legs
- 10pm:
 - Settled back into his bed while taking his pulse
 - Washington's fingers dropped off his wrist and he took his last breath
 - Lost 40% of his blood volume to blood letting
- Died at age 67
- 30 months after his retirement from Presidency

Ulysses S. Grant (1869-1877)

Diagnosis: Oropharyngeal Cancer

- **June 1884** (7 years after leaving office)
 - 62 years old
 - Heavy cigar smoker (12/day), heavy drinker
 - Began complaining of a sore throat
 - Delayed seeing his PCP
- **Oct 22, 1884**
 - PCP evaluated and referred him to a “throat specialist”
 - Dr. J. Douglas described a right tonsil mass as “*serious epithelial trouble*”



Ulysses S. Grant (1869-1877)

Diagnosis: Oropharyngeal Cancer

- **Initially treated:**
 - Cessation of smoking
 - Topical Iodoform and salt water gargles
 - Dilute carbolic acid gargle
 - Gargles composed of permanganate of potash/yeast
 - 4% topical cocaine for pain relief
- **Dec. 1884**
 - Tumor had spread to include tongue base and palate
 - Eating became difficult
- **Feb. 1885**
 - A biopsy was obtained, SCCA was diagnosed
 - Surgical resection would require mandibulectomy
 - Surgeons were not inclined to operate

Ulysses S. Grant (1869-1877)

Diagnosis: Oropharyngeal Cancer

- **March 1885**

- Tumor had progressed, having episodes of bleeding
- Slept upright at night
- Communicated using pen/paper

- **Spring 1885**

- Began writing memoir
- Persuaded by his friend Mark Twain



Ulysses S. Grant (1869-1877)


Diagnosis: Oropharyngeal Cancer

- June 1885
 - Grant was moved to Mt. McGregor, resort in NY
 - Completed his memoirs 3 days prior to death
- Grant died July 23, 1885 at age 63

Grover Cleveland (1885-89, 1893-97)

Diagnosis: Hard Palate Cancer

- May 1893, age 56
 - After inauguration for 2nd term, saw his physician for pain of the roof of mouth
 - Dr. O'Reilly (WH physician) found an ulceration of the left palate, took two “scrapings”
 - Diagnosed as “epithelioma”
 - Prominent surgeon, Dr. Joeseeph Bryant, recommended surgery



Grover Cleveland (1885-89, 1893-97)

Diagnosis: Hard Palate Cancer

- 1893 “the Panic”
 - Serious economic depression in the U.S.
 - Cleveland did not want to worry the American people for fear of further economic collapse
 - Had to keep his medical condition a secret

Grover Cleveland (1885-89, 1893-97)


Diagnosis: Hard Palate Cancer

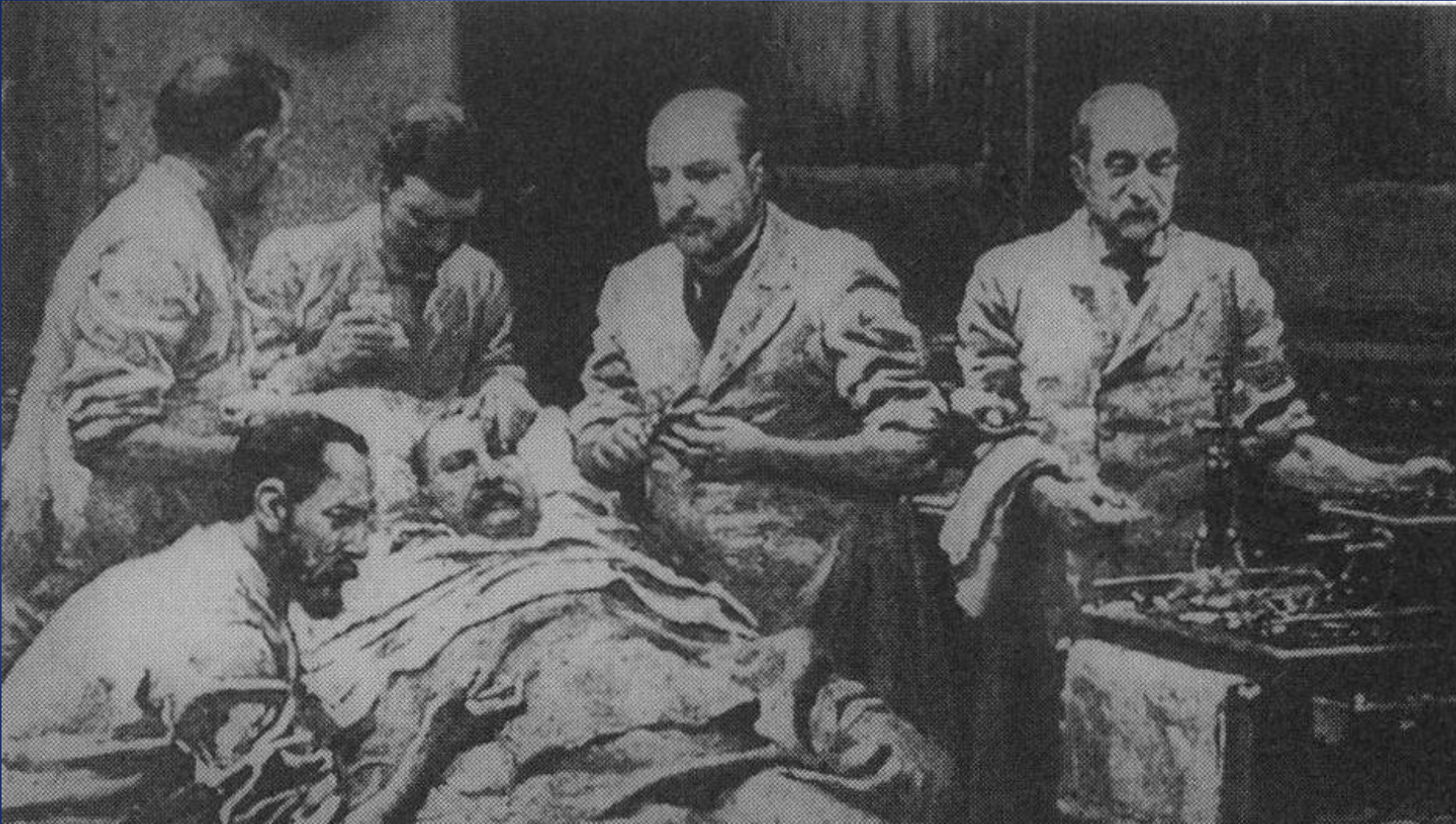- Evening of June 30, 1893
 - Cleveland boarded a friend's yacht, *the Oneida*, in East River outside of New York
 - Multiple physicians were on board
 - Dr. Bryant (surgeon)
 - Dr. Keen (Neurosurgeon)
 - Dr. Hasbrouk (Dentist, expertise in nitrous oxide)
- All had taken an oath of secrecy!*

Grover Cleveland (1885-89, 1893-97)

Diagnosis: Hard Palate Cancer

- June 31, 1893 – On board the Yacht, *Oneida*
 - Operation performed in the saloon, which was converted into an operating room
 - Procedure: *Intraoral Partial Maxillectomy*
- 12:30pm – Operation began
 - Nitrous oxide and Ether were administered
 - Dental extraction of two bicuspids
 - Partial Maxillectomy performed (using chisels)
 - No external incisions
 - 180 cc's blood loss
- 1:30pm – Operation complete
 - Cleveland remained in the yacht for 5 days recovering





Grover Cleveland (1885-89, 1893-97)

Diagnosis: Hard Palate Cancer

- July 5, 1893 (postop Day 5)
 - *Oneida* docked at Buzzards bay, NY
 - Cleveland was in good spirits, but couldn't speak with the large intraoral packing
 - Reporters were told he had a cold and tooth ache
- July 17, 1893
 - Returned for second minor surgery and obturator was fitted
 - President's voice returned to normal
- Cleveland went on to serve out his term and had no recurrence
- Died on June 24, 1908 at age 71 (heart failure)

Operation remained a secret until 1917 when Dr. Keen released his story in the *Saturday Evening Post* !

1892


A.T. Still opens the first Osteopathic School
Kirksville, MO



William Taft (1909-1913)

Diagnosis: Obstructive Sleep Apnea

- Served as 27th President and Chief Justice
- Weighed > 300lbs his entire Presidency
- BMI: 42
- Neck circumference: 19 in.
- “could sleep anywhere”
 - Sleep during conversations with Speaker of the House, with the Chief Justice
 - Would sleep at church, while dining out, while signing documents
- Other symptoms: HTN (SBP 210mmHg) and ADHD



William Taft (1909-1913)

Diagnosis: Obstructive Sleep Apnea


- Taft's illness was not recognized by his physicians
 - OSA wasn't described until *1965*
 - First CPAP wasn't introduced until *1981*
- Taft's closest aide, Major Archibald Butt, felt a duty to keep him awake in Public
 - Would stay near Taft at all times
 - Hard nudge, dropping objects or coughing



William Taft (1909-1913)

Diagnosis: Obstructive Sleep Apnea


- Taft lost re-election in 1912
(probably saved his life)
- Free of the strains of the White House, his weight dropped from **340lbs** to **262lbs** in a year
 - he kept the weight off for the rest of his life
 - His daytime sleepiness vanished, HTN resolved
- In the last 9 years of his life, he was a very effective and productive Chief Justice on Supreme Court
- **He died at the age 72**



Franklin D. Roosevelt (1933-1945)

Diagnosis: Chronic Sinusitis

- 32nd President
- August 1921
 - Became ill, ascending paralysis
 - Diagnosed with Poliomyelitis
 - (Symptoms may have been more consistent with Guillain-Barre syndrome)
- During the remainder of his life, he was plagued with chronic sinusitis !



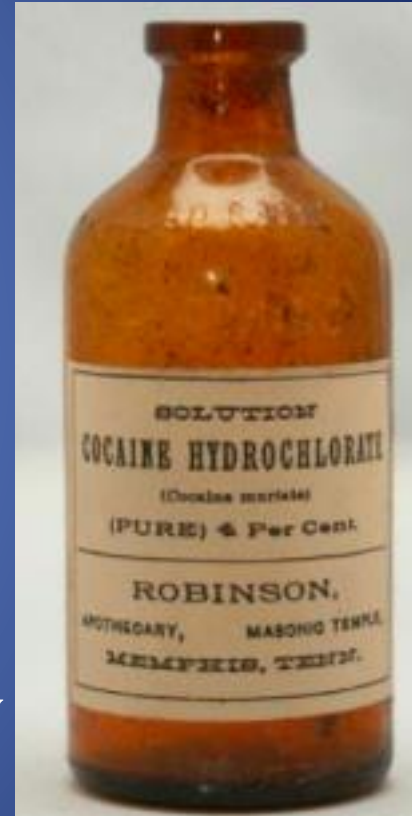
Franklin D. Roosevelt (1933-1945)

Diagnosis: Chronic Sinusitis

- FDR's personal physician, Dr. Ross McIntire, was an otolaryngologist
 - Would accompany FDR to WH meetings, War time conferences, etc
- Sinus Treatment options in 1940's
 - Sinus irrigations and lavage
 - No antibiotics available
 - Topical intranasal cocaine used routinely

(not the 4% topical cocaine mix we use today)

Patients were not told they were being treated with cocaine for fear they would become addicted



Franklin D. Roosevelt (1933-1945)

Diagnosis: Chronic Sinusitis

- Dec 7, 1941 – Attack on Pearl Harbor
- Dec 8, 1941 - “Day of Infamy” Speech
 - FDR was suffering from severe sinus infection
 - Dr. McIntire (ENT) was treating FDR 70 min prior to his speech



“Yesterday, December 7th, 1941—a date which will live in infamy—the United States of America was suddenly and deliberately attacked by naval and air forces of the Empire of Japan.”

- It is likely FDR was treated with intranasal Cocaine prior to his famous speech!



Ronald Reagan (1981-1989)

Diagnosis: Noise Induced Hearing Loss

- 40th President
- Hollywood Actor
- Suffered acoustic trauma while on a movie set
- .38 caliber blank was fired close to his right ear



Ronald Reagan (1981-1989)

Diagnosis: Noise Induced Hearing Loss

- Dr. John House (ENT) had been treating Reagan's hearing loss since 1979
 - House Ear Institute in California
 - World renowned hearing clinic
- **August 1983**
 - Became first President to publicly wear a Hearing Aid !

REAGAN BEGINS TO WEAR A HEARING AID IN PUBLIC

Ronald Reagan (1981-1989)

Diagnosis: Noise Induced Hearing Loss

- Timing of the announcement of Reagan's use of hearing aids came at a time when the Hearing equipment industry was in recession.
 - Resulted in increased sales
 - Reduced stigma associated with hearing aids

Ronald Reagan (1981-1989)

Diagnosis: Noise Induced Hearing Loss



- Reagan declared **May 1986** as *“Better Hearing and Speech Month”*
- 1988, Reagan was fitted with a new set of hearing aids
- Featured a not-yet-released remote control
 - Secret Service was paranoid that the remote control would allow foreign spies to eavesdrop on Reagan’s conversations



Resources

- Arch Otolaryngol Head Neck Surg. 2010;136
- Journal of Royal Society of Med 1995, Vol 88
- Up to date Acute Otitis Media, Chronic otitis media, Tonsillectomy
- Up to date Neck mass, Oropharyngeal ex Sialoadenitis, Nasal congestion
- CDC online guidelines